

Cannulation (adult): At a glance

Written by

Claire Ford - Lecturer, Adult Nursing, Northumbria University

This article will:

- Provide clinical guidance on performing cannulation on an adult
- Discuss site and equipment selection
- Demonstrate the clinical procedural technique of cannulation
- Provide an awareness of the dangers and complications of this invasive technique

Why do healthcare professionals need to learn how to conduct cannulation?

Intravenous cannulation is a technique that involves the insertion of a fine flexible hollow tube, with an inner retractable needle, into a peripheral vein and worldwide, is the most commonly performed invasive procedure (Boyd, 2013). It provides access for the administration of fluids, medications, dyes, contrast media, and blood products, and enables the removal of blood for analysis (Helm *et al.*, 2015). However, undertaking cannulation carries risks; therefore, in order to practice safely, it is paramount that healthcare professionals are cognisant of their own limitations, understand the theory underpinning the insertion technique, and have an awareness of the risks associated with this clinical skill (NMC, 2015).

Informed consent and patient preparation

Where possible, informed consent should be obtained. This will include ensuring that patients are aware of: the reasons for the cannula, the areas where it could be situated, what the associated risks and complications are and details of the insertion procedure and aftercare (Dougherty and Lister, 2015). Providing this level of information will not only safeguard that the patient can provide valid

consent, but it will also assist in building rapport and a trusting therapeutic relationship, which could help reduce any fears or anxieties.

Anatomy of the hand and forearm

Unlike venepuncture and where possible, the antecubital fossa region should be avoided. Especially for cannulas that will be sited for longer periods, as flexion of the arm may impede the ability of the cannula to function correctly and increase the possibility of the cannula becoming occluded. Rickard (2012) agree that occlusion is one of the most common reasons for cannula failure and may lead to the patient experiencing unnecessary discomfort if the cannula needs to be removed and resited. It is, therefore, best practice to use the Cephalic or Basilic veins on the forearm, (see image one) or the dorsal metacarpal veins on the back of the hand (see image two) (Thomas, 2015).

Choosing the correct site, vein and cannula size

The National Institute for Health and Care Excellence (NICE) (2013) recommend that before insertion of a cannula, a clinical decision in relation to the site and choice of vein needs to be undertaken by the healthcare professional undertaking this task, in order to reduce the risk of cannula failure and associated complications. The decision should take into consideration the patient's preferences, their level of acuity, vein accessibility, medical history and cannulation history. Sites and veins to avoid include those affected by the patient's clinical condition, such as post-mastectomy, as using the side associated with breast surgery is contraindicated due to the complications associated with potential lymphoedema development post node removal (Thomas, 2015). Veins, which are small, superficial, sclerosed, pulsate or close to arteries should also be avoided, in order to reduce the risks of complications developing during and after the insertion period (Rickard et al., 2012). Complications can also be avoided by using veins with a larger diameter, in the upper extremities and with good capillary refill (Dougherty and Lister, 2015). Factors that would affect the decision for the site and the vein choice have been summarised in *figure 1*.

Moreover, in an attempt to improve vessel health, it is vital that healthcare professionals possess knowledge and understanding of alternative vascular access devices, and utilise the vessel health and preservation (VHP) framework, in order to assess whether a peripheral cannula is the most appropriate device to use (Hallam *et al.*, 2016). If a peripheral cannula is the most suitable vascular access device, then it is important to choose the correct size (length and width) and type (ported or non-ported). Thomas (2015) advocates that healthcare professionals should use the shortest and smallest gauge capable of achieving the required flow rates in order to meet the clinical need. Because there are a vast array of devices available, from several manufacturers, it is also important to take into consideration specific design features (such as wings and ports) when choosing which device to use.

Cannula insertion procedure

In order to carry out the procedure, additional equipment is required (see figure 2), all of which should be checked prior to carrying out the procedure.

- 1) Communicate with the patient and provide them with relevant information in order for them to provide informed consent. This will also provide you with the opportunity to talk about previous experiences with cannulation, ascertain if the patient has any allergies to dressings, assess for potential complications and physically prepare the patient and the environment prior to collecting the equipment.
- 2) Decontaminate hands, and with the patient's arm in a comfortable and appropriate position, apply the tourniquet 7-10 cm above the chosen site. To encourage venous filling and vein distention, ask the patient to open and close their fist, use gravity by asking the patient to hang their arm down, apply a warm compress, or lightly stroke the vein in a downward motion (Phillips and Gorski, 2014).

- 3) With two fingers, palpate the vein in order to confirm suitability (see image 3.1) and release the tourniquet.
- 4) Decontaminate hands, clean the tray/receptacle and gather the equipment, ensuring that you check for damage and contamination. Place equipment into the clean receptacle using the aseptic non-touch technique (ANTT) (do not touch the key parts - the tip of the cannula and the end of the syringe for flushing).
- 5) Reapply the tourniquet; do not over tighten as this may obstruct arterial flow.
- 6) Clean the chosen site with the alcohol-based (2% chlorhexidine in 70% isopropyl alcohol) preparation equipment (see image 3.2). Ensure that you abide by the manufactures application instructions and allow to dry for 30 seconds. Do not touch the skin or re-palpate the vein after application of the skin preparation (Dougherty and Lister, 2015).
- 7) While waiting for the skin preparation solution to dry, decontaminate hands and don gloves.
- 8) Prepare the cannula device by removing the needle guard and assessing the tip for damage.
- 9) Then with your non-dominant hand apply traction to the skin and stabilise the vein below the chosen site. Advise the patient that they will feel a sharp scratch.
- 10) Insert the cannula at an angle of 20-30 degrees (depending on manufactures instructions) ensuring that the bevel is up and observe for the first flashback of blood into the cannula (see image 3.3).
- 11) Lower the angle of insertion by dropping the cannula closer to the skin and advance the device slightly.
- 12) Then continue to advance the cannula 2 mm and draw the stylet back 2-3 mm noting the second flashback in the lumen of the cannula (see image 3.4).
- 13) Slide the cannula over the needle, advancing further into the vein. Keeping traction on the skin will make this process easier.
- 14) Release the tourniquet, apply pressure beyond the cannula tip, loosen the cap at the end of the stylet and withdraw the needle, placing it immediately into the sharps waste container. In line with the

Health and Safety Executive (2013) regulations, the cannula will have a safety device (active or passive) in place to prevent a sharps injury. Depending on the specific design, it may also have a passive safety feature that prevents the reinsertion of the needle back into the lumen of the cannula, reducing the risk of cannula tip damage (see image 3.5). Reapply the cap before releasing pressure and fix the cannula in place with a semi-permeable film dressing.

- 15) Flush with 0.9% sodium chloride (procedure for how this is undertaken will differ if using an extension set, or an integrated cannula), and ensure patient comfort.
- 16) Dispose of waste, remove PPE and decontaminate hands using the appropriate technique (Ford and Park, 2018; 2019).
- 17) Document your care (via paper-based or electronic platforms) according to Trust guidelines and protocols. This should include, as a minimum standard, your signature, date and designation, the time, cannula size, site of insertion, the number of insertion attempts, and any noted insertion complications. Further documentation such as the VIP score may also need to be completed, depending upon Trust requirements.

Risks and hazards

Research by Wallis *et al.* (2014) and Helm *et al.* (2015) suggest that catheter-related failure complication rates vary from between 35%-50%. These can be avoided if healthcare professionals adhere to sound infection control and prevention precautions, choose the right vessel, use correct insertion techniques, and have an awareness of the anatomy (Dougherty and Lister, 2015). Additionally, as with any clinical procedure, the appropriately trained person must be aware of the risks involved, not only for themselves but also to the patient and others.

Safety of the Practitioner

One of the greatest dangers to healthcare professionals when undertaking procedures using hollow-bore needles, is the risk of contracting a blood-borne infection via a sharps injury (Health and Safety

Executive, 2013). Due to the frequency of undertaking cannulation, nurses are one of the healthcare professional groups most at risk (Woode, 2015). Healthcare professionals can be exposed to 30 potentially dangerous pathogens, including Hepatitis B and C (European Biosafe Network, 2011). Therefore, in order to ensure safe practice, personal protective equipment, which is a universal precaution, must be worn. Kinlin *et al.* (2010) claim that the use of gloves has been shown to be beneficial in reducing the transmission of blood-borne infections by decreasing the inoculum of blood introduced during a sharps injury. Additionally, all devices used must adhere to sharp safety regulations, must be checked before use, used as instructed by the manufactures and disposed of correctly (Health and Safety Executive, 2013).

Safety of the patient

The risks of inserting a foreign object into a patient's arm must be considered, especially in relation to the risk of complications such as infection, haematoma, arterial puncture, and nerve injury and what steps must be taken if they occur (Buowari, 2013).

The following list (which is not exhaustive) provides a brief overview of some of the complications associated with peripheral vascular cannulation during insertion and in the post-insertion period.

Insertion complications

- **Nerve Injury** – This can occur through poor vein choice and often results in shooting or burning pain, or sharp tingling. If this occurs, the needle and tourniquet must be removed.
- **Haematoma** – Infiltration of blood into the surrounding tissues is often caused by poor insertion technique, inappropriate vein selection, inadequate pressure upon removal, incorrect use of the tourniquet or a cannula size, which is too large for the chosen vein. The risk of this occurring is increased in a patient who is receiving anticoagulant therapy.

- **Arterial Puncture** – the inadvertent puncture of an artery rather than a vein can occur if there has been an inadequate assessment of the site and a vein chosen, which is very close to an artery. This can result in the formation of a hematoma and other symptoms such as numbness, pain, paleness and coldness of the limb or hand. If an arterial puncture occurs, remove the cannula, apply pressure and raise the patient's arm.

Post insertion complications

- **Phlebitis** – This is defined as irritation or inflammation of the vein, caused by chemical, mechanical or biological means. Patients can display a range of symptoms; which can include localised pain, oedema, and erythema. If this occurs and depending on the visual infusion phlebitis (VIP) score, the cannula may need to be removed and resited. To aid with the discomfort and swelling that can be experienced, a warm or cold compress can be applied.
- **Thrombus** – In some cases, a thrombus may develop within the vein that has been used for cannulation. A thrombus can also occur secondary to phlebitis (thrombophlebitis), and it may be necessary to remove and resite as per the VIP protocol.
- **Infiltration** – This relates to the administration of non-vesicant medication and fluids into the adjacent tissue rather than the vein (Phillips and Gorski, 2014). The severity of the complications is usually graded using the infiltration scale, and close monitoring of the patient, cannula site and surrounding tissue will be needed, to assess deterioration or improvement. The VIP score will also need to be recorded.
- **Extravasation** – This complication is defined as the administration of vesicant intravenous fluids or medications into adjacent tissues rather than the vein, which subsequently leads to blistering and possible tissue necrosis (Phillips and Gorski, 2014). Immediate signs include a slowed infusion rate, pain, oedema, and skin blanching. If extravasation occurs, the infusion of fluid or medication must be stopped immediately and advice sought in relation to whether the fluid or medication needs to be aspirated. In some cases, the cannula will, therefore, need to

remain in situ for aspiration and antidote administration to occur. As in the case of phlebitis, warm or cold compresses might be beneficial, and limb elevation may be required due to oedema.

- **Air Embolism** – This occurs when air or gas is admitted, iatrogenically, into the vascular or arterial system and whilst it is rare, it can be fatal. In the case of cannulation, it can be avoided by the correct priming of the fluid administration set so that no air enters the bloodstream. Signs and symptoms include tachypnea, reduced oxygen saturations, hypotension, tachycardia and chest pain.

(Rickard et al., 2012; Dougherty and Lister, 2015 and RCN, 2016)

Top tips

The following information has been collated by Northumbria University staff in relation to some of the common errors that students encounter when undertaking cannulation in clinical practice.

1. **Missed Vein** – ensure you use your fingers to anchor the vein, below the intended insertion point, as this will prevent the vein from moving and ensure easier entry. Also, spend time assessing the site and locating the most optimal vein. If you choose one of the largest veins, then the likelihood of missing the vein will be reduced.
2. For veins that are difficult to locate, use additional assistive technologies such as vein location tools and ultrasound, which can be used with assistance from a trained operator.
3. If blood is required for analysis, this must be taken prior to the administration of any medication. Please refer to the associated article "*Venepuncture: Art a glance*", for further details on the procedure for taking blood (Skarparis and Ford, 2018).
4. Consider whether a peripheral cannula is the best device for the delivery of fluids and medications. Utilise the VHP framework and continually re-evaluate vessel health.

Conclusion

Cannulation is a clinical skill, which requires healthcare professionals to have a sound understanding of the underpinning principles, as well as a comprehensive awareness of the technique aligned with the clinical procedure. Therefore, whilst it is important to review local and national guidelines and associated literature, it is also vital to use every opportunity to practice this skill in clinical practice, in addition to using alternative education and learning strategies such as simulation-training aids, in order to maintain contemporary practice (NMC, 2019).

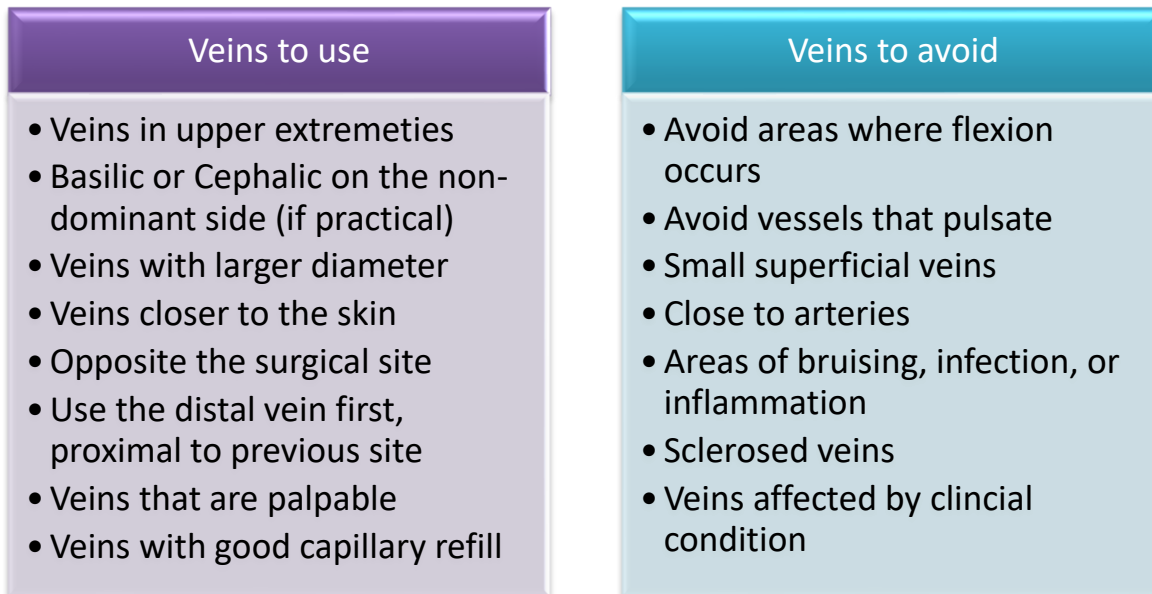
Image 1

Insert anatomical diagram of the Cephalic and Basilic veins in the forearm.

Image 2

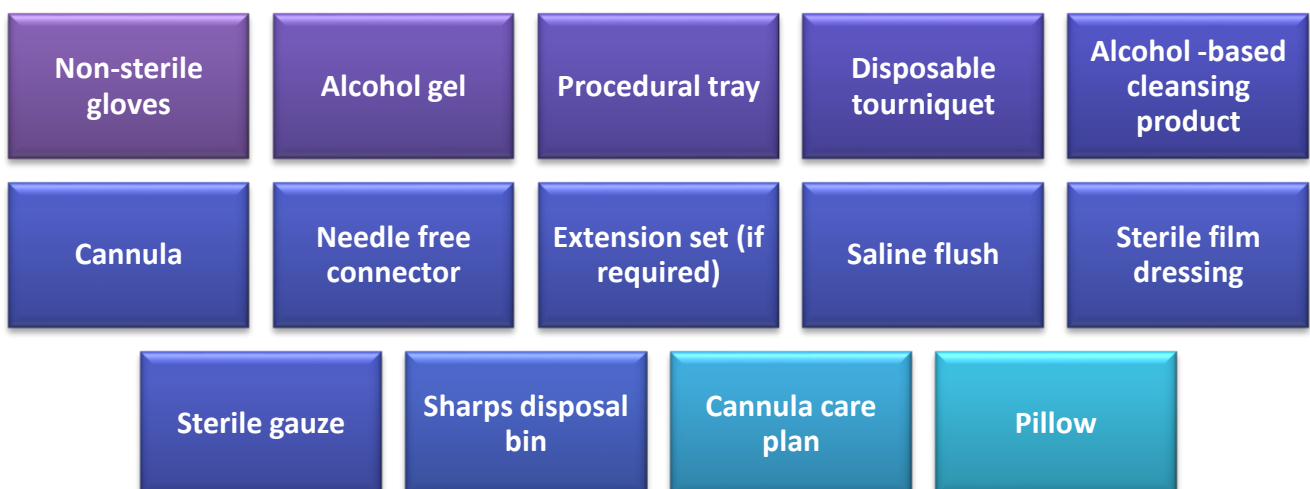Insert anatomical diagram of the dorsal metacarpal veins on the hand

Figure 1



(Rickard *et al.*, 2012; Dougherty and Lister, 2015; Thomas, 2015)

Figure 2



(Dougherty and Lister, 2015)

Images (the below images are the property of Northumbria University, and we give permission to the BJN to use these in this publication)

Image 3.1

To be retaken

Image 3.2

To be retaken

Image 3.3

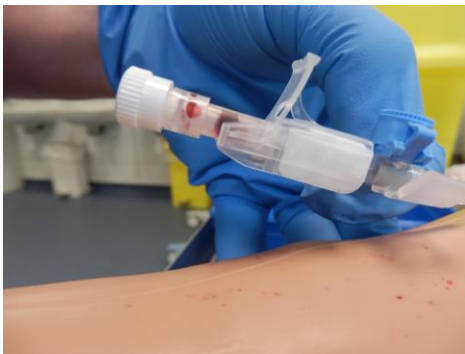

Image 3.4

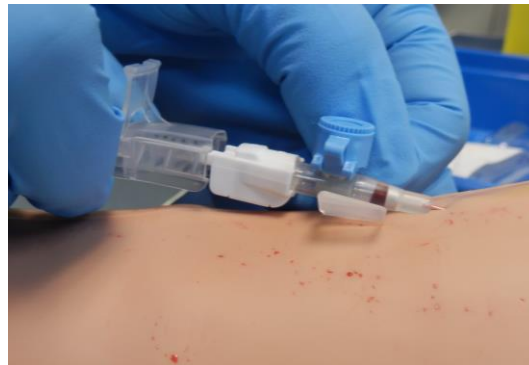
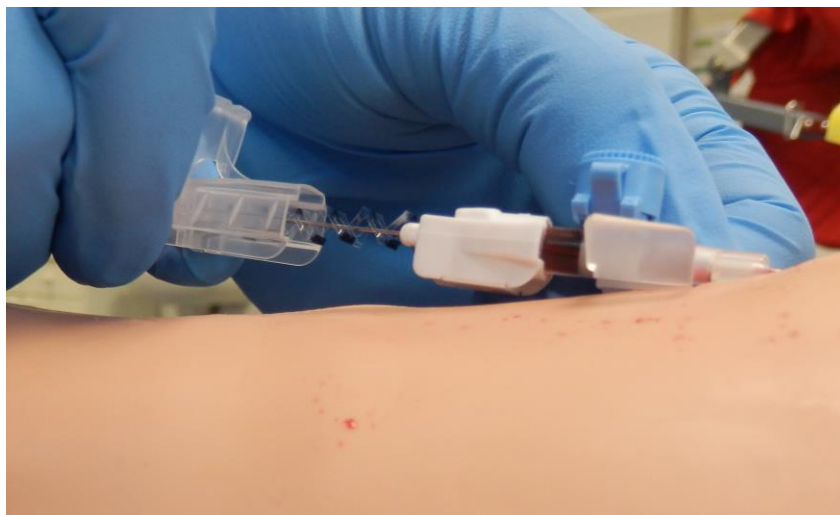
Image 3.5



References:

- Boyd, C. (2013) *Clinical skills for nurses*. West Sussex: Wiley.
- Buowari, O. Y. (2013) 'Complications of venepuncture', *Advances in Bioscience and Biotechnology*, 4, pp. 126-128.
- Dougherty L, and Lister S. (2015) *The Royal Marsden Hospital manual of clinical nursing procedures*. 9th edn. West Sussex: Wiley.
- European Biosafety Network (2011) *Prevention of sharps injuries in the hospital and healthcare sector. Implementation guidance for the EU Framework Agreement, Council Directive and associated national legislation*. Available at: www.europeanbiosafetynetwork.eu (Accessed: July 2018).
- Ford, C. and Park, L. G. (2018) 'Hand hygiene and handwashing: key to preventing the transfer of pathogens', *British Journal of Nursing*, 27(20), pp. 1164-1166.
- Ford, C. and Park, L. G. (2019) 'How to apply and remove medical gloves', *British Journal of Nursing*, 28(1), pp. 65-72.
- Hallam, C. *et al.* (2016) 'Development of the UK vessel health and preservation VHP framework: a multi-organisational collaboration', *Journal of Infection Prevention*, 17(2), pp. 65-72.
- Health and Safety Executive (2013) *Sharp Instrument in Healthcare Regulations 2013: guidance for employers and employees*. Health and Safety Executive Publications.
- Helm, R. E. *et al.* (2015) 'Accepted but Unacceptable: Peripheral IV Catheter Failure', *Infusion Nurses Society*, 38(3), pp. 189-203.
- Kinlin, L. M. *et al.* (2010) 'Use of gloves and reduction of risk of injury caused by needles or sharp medical devices in healthcare workers: results from a case-crossover study', *Infect Control Hosp Epidemiol*, 31(9), pp. 908–17.
- NICE (2013) *Intravenous fluid therapy in adults in hospital*. London: NICE.

- NMC (2018) *The Code*. London: NMC.
- NMC (2019) Standard framework for nursing and midwifery education. London: NMC.
- Phillips, L.D. and Gorski, L. A (2014) *Manual of I.V. Therapeutics: Evidence-Based Practice for Infusion Therapy*. 6th edn. Philadelphia: F.A. Davis Company.
- Rickards, C. R. *et al.* (2012) 'Routine versus clinically indicated replacement of peripheral intravenous catheters: a randomised controlled equivalence trial', *The Lancet*, 380, pp. 1066-1074.
- Royal College of Nursing (RCN) (2016) *Standards for infusion therapy*. 2nd edn. London: RCN.
- Skarparis, K. and Ford, C. (2018) 'Venepuncture in adults', *British Journal of Nursing*, 27(22), pp. 1312-1315.
- Thomas, R. K. (2015) *Practical Medical Procedures at a Glance*. West Sussex: Wiley.
- Wallis, M. C. *et al.* (2014) 'Risk factors for peripheral intravenous catheter failure: A multivariate analysis of data from a randomized control trial', *Infection Control and Hospital Epidemiology*, 35(1), pp. 63-68.
- Woode, O. M. *et al.* (2015) 'Bloodborne viruses and workplace injury risk', *Nursing Times*, 111(7), pp. 12-14.