

Northumbria Research Link

Citation: Hood, Wendy and Hood, Martin (2016) Can eyes cause neck pain? International Journal of Therapy and Rehabilitation, 23 (10). pp. 499-504. ISSN 1741-1645

Published by: Mark Allen Publishing

URL: <http://dx.doi.org/10.12968/ijtr.2016.23.10.499>
<<http://dx.doi.org/10.12968/ijtr.2016.23.10.499>>

This version was downloaded from Northumbria Research Link:
<http://nrl.northumbria.ac.uk/28627/>

Northumbria University has developed Northumbria Research Link (NRL) to enable users to access the University's research output. Copyright © and moral rights for items on NRL are retained by the individual author(s) and/or other copyright owners. Single copies of full items can be reproduced, displayed or performed, and given to third parties in any format or medium for personal research or study, educational, or not-for-profit purposes without prior permission or charge, provided the authors, title and full bibliographic details are given, as well as a hyperlink and/or URL to the original metadata page. The content must not be changed in any way. Full items must not be sold commercially in any format or medium without formal permission of the copyright holder. The full policy is available online: <http://nrl.northumbria.ac.uk/policies.html>

This document may differ from the final, published version of the research and has been made available online in accordance with publisher policies. To read and/or cite from the published version of the research, please visit the publisher's website (a subscription may be required.)

www.northumbria.ac.uk/nrl



Sensory Integration: Can eyes cause neck pain?

Abstract

This article is an analysis of literature relating to ocular-motor imbalance and the potential postural consequences. It aims to highlight the importance of sensory integration between the visual and vestibular systems and proprioception. The consequences of extra-ocular muscle imbalance are discussed in terms of the disruption to this sensory integration. The symptoms that this may give rise to include spinal pain, postural instability and potential increased risk of falls. This paper therefore encourages a wider multi-disciplinary awareness in managing patients with such symptoms.

Key Words: sensory integration; ocular torticollis; neck pain.

Introduction

Neck and back pain can have numerous possible aetiologies, one presentation of which could be torticollis. Torticollis is a Latin term, which literally means 'twisted column' and in a clinical context refers to a neck, which is held in an abnormal position. In musculo-skeletal clinical practice this may not respond to usual management strategies. Slight torticollis might go relatively un-noticed or be dismissed as a postural idiosyncrasy. However, it could be related to an ocular muscle-balance problem and the consequences of this could potentially extend beyond simple neck pain. Lau et al (2009) report that 22.6% of non-orthopaedic torticollis have an ocular cause. If eye muscles do not co-ordinate the eyes correctly (i.e. there is an ocular-motor imbalance), then this can give rise to a squint (also known as strabismus), where the eyes may be convergent (crossed), or divergent, or vertically misaligned. Note that this has nothing to do with the colloquial "squint" where eyes are merely screwed up against the sun or to see more clearly. Clinically this phenomenon is important to be aware of, because if a patient has a squint, this may lead to an altered head position (AHP), which in turn could have musculoskeletal consequences, including neck pain and even scoliosis or chronic low back pain. In these situations, whilst simple stretches or advice about positioning may provide symptomatic relief on a short-term basis, liaison with an optometrist or orthoptist may be appropriate to investigate the under-lying aetiology.

Much more subtle ocular misalignment and reduced stereopsis (3-D awareness) can affect postural stability and possibly contribute to chronic back pain (Matheron & Kapoula, 2011). This reduction in stereopsis and associated postural instability could also increase the risk of falls (Buckley et al., 2010).

The aims of this article are:

1. to raise awareness, amongst physiotherapists and rehabilitation clinicians, of ocular torticollis;
2. to indicate consequences of such an induced AHP;
3. to introduce possible consequences of subtle oculo-motor imbalance on postural stability;
4. to encourage, therefore, a multi-disciplinary communication between rehabilitation and ophthalmic professionals.

Ocular Mechanics

This section will give an introduction to eye muscle anatomy and action in order to aid understanding of the link between abnormal eye movements and neck pain. Each eye has six extra-ocular muscles, (see figure 1), which allow the eye to move laterally, vertically and torsionally. The primary and secondary actions of each muscle varies depending upon the position of the eye; for example the lateral rectus, which is a pure abductor when the eye is in primary, straight-ahead gaze, also becomes an elevator in elevated gaze, with some small excyclorotatory action (top of eye rolls temporally). Clinically, therefore, if a patient has right lateral rectus muscle weakness (which could be caused by a right VIth cranial nerve damage) then the patient is likely to experience double vision. This double vision (diplopia) will be exaggerated when attempting to gaze to the right. To maintain binocular fixation, eyes need to move in tandem; thus stimulation of the right lateral rectus (for abduction) is paired with stimulation of the yoke muscle, the left medial rectus (for adduction), according to Hering's Law. (Kanski, 1994). Hence, understanding the actions of the muscles can also help to explain the potential altered head position that the patient may adopt in an attempt to avoid double vision.

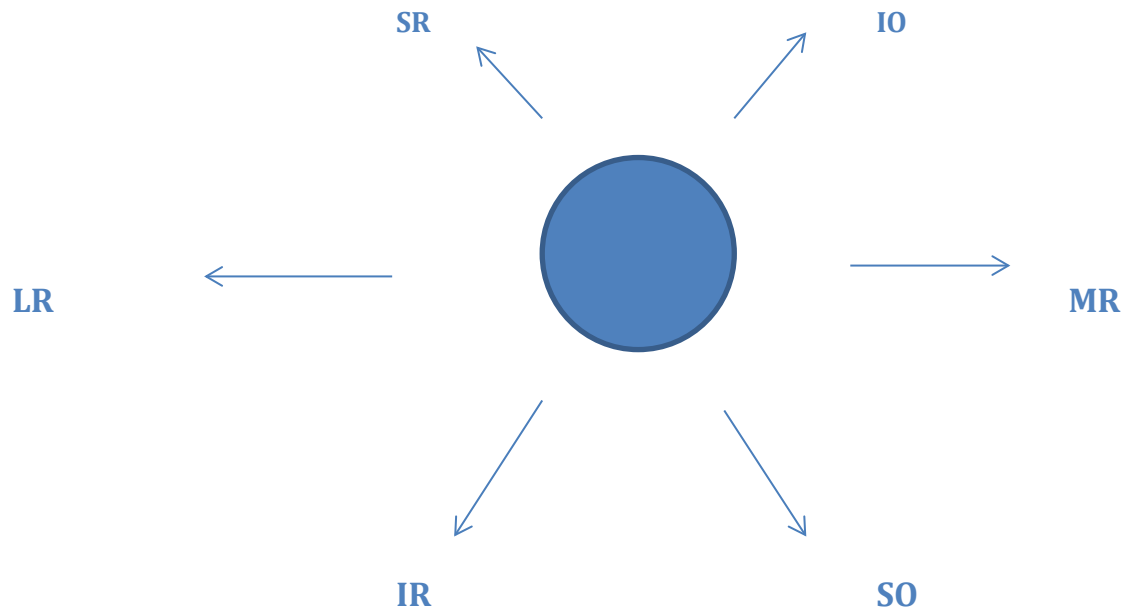
If a single extra-ocular muscle is weakened or palsied (temporarily, perhaps due to a diabetes – related haemorrhage in the muscle itself, or permanently due to lesion of the innervating cranial nerve) then the associated eye-movement will be affected and ocular axes will misalign. Note that the size of this mis-aligning squint may be small and therefore not always immediately obvious to a casual observer. Here, where the size of the squint is dependent on the direction of gaze, the squint is described as incomitant. It is an incomitant squint, which may lead to an abnormal head posture. In contrast, a comitant deviation is where the angle of squint is stable whatever the direction of gaze. A comitant deviation is a common developmental abnormality, usually in response to the need for spectacles, and/or a consequence of anatomical misalignment of visual axes (Pickwell, 1984). Comitant deviations are usually associated with a weaker, blurred, amblyopic (or lazy) eye, which also therefore prevents development of good stereopsis. The importance of stereopsis is addressed later in this article.

Note that a small angle of deviation, but without squint, between the visual axes is normal and termed heterophoria. Sensory recognition of this disparity usually causes a change in extra-ocular muscle tone to realign the axes, to compensate for the deviation. If the heterophoria is not compensated, then a squint becomes manifest. Decompensation is more common in larger heterophoria angles, particularly if they are vertical, and in general fatigue/ debilitation. Heterophoria without abnormal head posture may cause subtle changes in posture as described later in the section entitled 'Postural Instability'. The neurological mechanism that links these eye problems with posture is described in the following section on sensory integration.

Fig. 1 Right eye extra-ocular muscles, with arrows indicating primary direction of action.

The circle in this diagram represents the eye as observed when looking at the person's face.

Thus LR (lateral rectus) action causes the right eye to turn towards the right ear.



SR = superior rectus (III cranial nerve innervation)

IO = inferior oblique (III)

LR = lateral rectus (VI)

MR = medial rectus (III)

IR = inferior rectus (III)

SO = superior oblique (IV)

Sensory Integration

In order to understand the range of potential consequences that oculomotor imbalance can have, it is first necessary to understand the way in which different senses are integrated to achieve balance. Balance, or equilibrium, is the result of a complex mechanism, which involves integration of information from the visual system, vestibular system and proprioceptors. For example, a potential consequence of mismatch between information from the vestibular, proprioceptive and visual systems is visual vertigo, which often manifests as travel sickness (Sawle, 1996). Such visual vertigo can be more commonly found in people with squint (Bronstein, 1995).

Reflexes transmitted through the vestibular nuclei and the medial longitudinal fasciculus to the oculomotor nuclei, ensure that the eyes remain stable and fixed on an object in spite of head movement. This is done via signals from the semi-circular canals, which cause the eyes to move to an equal degree in the opposite direction to the rotation of the head (Guyton & Hall, 2006).

Proprioceptive signals, particularly from the cervical spine, are also very important in the maintenance of equilibrium. The neck region has significantly more muscle spindles per gram of muscle than other regions of the body, which demonstrates the important proprioceptive role of the

neck (Treleaven, 2008a). When the head (but not the whole body) moves to one side, proprioceptive signals from the cervical spine are integrated with those from the vestibular system in order to prevent this head movement from disrupting a sense of postural balance. The vestibular apparatus provides the brain with information about movement and positioning of the head. Proprioceptive signals from the neck and body transmit information directly to the vestibular and reticular nuclei in the brainstem (and indirectly via the cerebellum) providing information about the position of the head relative to the rest of the body (Guyton & Hall, 2006). The cerebellum coordinates signals from the visual system, vestibular apparatus and proprioceptive receptors allowing body position to be perceived. The cerebellum also transmits impulses to the cerebrum and musculoskeletal system to initiate postural adaptations to be made in order to maintain equilibrium (Waugh & Grant, 2014).

Musculoskeletal proprioception and vestibular input described above orientate the body physically in space and this needs to be integrated with the visual perception of space to provide a multi-sensory construction. Vision appears to be the primary input in terms of relating to one's position in space in infancy (Legrand et al., 2011; Morningstar et al., 2005) and balance again becomes more visually dependent with age from the mid-forties onwards (Poulain & Giraudet, 2008). There is a suggestion that it may not just be sight that is important in terms of visual input to balance. Proprioceptive input from extra-ocular muscles may also be an important part of the visual postural control pathway, passing through the optic tract nucleus to the superior colliculus, which has an important role in head and eye orientation and coordination (Morningstar et al., 2005). The clinical implications of the proprioceptive input from extra-ocular muscles are addressed in the section on postural instability below.

Musculoskeletal Consequences of Incomitant Squint

The section above has described the integration of sensory inputs from the visual, vestibular and proprioceptive systems. These sensory inputs allow us to perceive the position of our body in space. Changes to any of these sensory inputs will initiate changes in muscle action to re-orientate the body in space. A torticollis of ocular origin (ocular torticollis) is a compensatory mechanism used in an attempt to achieve optimal vision without diplopia (double vision). Depending on the reason for the altered head position (AHP), the torticollis could involve neck flexion or extension, rotation or side flexion or a combination of any of these positions (Wright, 2007). There are several different visual problems, which might result in an AHP, for example nystagmus or uncorrected refractive error (Shapiro, 1994), but for the purposes of this review incomitant squint is the main focus as this is the primary ocular cause of abnormal head posture.

A long-standing AHP as a result of extra-ocular muscle dysfunction can cause adaptive muscle length changes around the cervical spine, which in turn can lead to postural changes including compensatory scoliosis of the thoracic and / or lumbar spine (Dietrich & Slack, 1967; Hilton, 1980; Lau et al., 2009). Scoliosis is an abnormal lateral curvature of the spine, and can be a cause of back pain. For example, right IV cranial nerve palsy, which is the most common cause of ocular torticollis

(Lau et al., 2009), will cause diplopia particularly when viewing down to the left (e.g. when reading) as this is the direction of action of the Superior Oblique muscle. This will cause a compensatory head tilt to the left, leading to shortening of the Sternocleidomastoid muscle (SCM) on the left, (Dietrich & Slack, 1967) and possible lengthening on the right SCM. In other words, the patient may experience tightness of the neck muscles on the left side, which could be a cause of neck pain, and the patient may be seen to hold their head tilted towards the left shoulder. In long-standing cases (for example where the IV cranial nerve palsy is congenital) the risk of developing a compensatory scoliosis in other areas of the spine is likely to be greater, possibly leading to complaints of pain in the thoracic and / or lumbar spine. Shapiro (1994) advocates good communication between Optometrists and Physiotherapists as correction of the postural problem is unlikely to be effective if the underlying cause (the ocular-motor dysfunction) is not addressed. This view is supported by Lau et al's (2009) finding that surgery on older patients with IV cranial nerve palsy was less successful than similar extra-ocular muscle surgery on younger patients in correcting the AHP, which correlated with a relationship between SCM tightness and residual torticollis. They therefore suggested that treating the SCM tightness may improve the outcome of extra-ocular muscle surgery. Therefore in this situation the clinical management requires both: eye muscle surgery to deal with the primary cause, and management of the secondary musculoskeletal consequences (such as neck muscle tightness and scoliosis). There appears to be a lack of literature exploring the effects of postural advice or exercise to alleviate the symptoms induced by long standing AHP. This is therefore an area which could benefit from future investigation. However there is experimental evidence of the potential consequences of squint not only on musculoskeletal pain, but postural instability, which is explored below.

Postural Instability

The wider impact of squint is not limited to musculoskeletal pain. There is evidence to suggest that ocular-motor dysfunction can also lead to reduced postural stability in both children (Lions et al., 2013) and adults (Przekoracka-Krawczyk et al., 2014). Przekoracka-Krawczyk et al (2014) suggest that it is not just the visual consequences of squint (such as diplopia), which might impact on postural stability, but the altered proprioceptive cues from the extra-ocular muscles. These conclusions came from a study assessing the postural stability of young adults with horizontal comitant squint. Another study measuring postural stability in adults with ocular torticollis secondary to vertical incomitant squint (Bellizzi et al., 2011) also found reduced postural stability in quiet stance affecting length of sway path, velocity of sway and sway area. Sway is postural movement as measured on a force plate, on which the subject is standing. Bellizzi et al (2011) also concluded that extra-ocular proprioception was important in postural stability as the length of sway path in adults with squint was significantly greater than that found in control subjects, and critically did not vary greatly between eyes open and eyes closed conditions. This suggests that vision was not the most important factor in this instance, but extra-ocular proprioception may have been more influential. This increased length of sway path indicates that there is more muscle activity in the lower limbs and therefore greater effort is required to stabilise the posture. Other areas of postural stability, such as velocity of sway and total sway area, appeared to be more vision-dependent, as these did show a significant difference between eyes open and eyes closed conditions, though both were significantly poorer than the control group. These studies show that even in the case of long-standing squint, postural stability mechanisms do not fully adapt to restore normal balance. This

emphasises how an error in visual input has a detrimental effect on posture via the perturbation of sensory integration as described previously.

Even when there is not a manifest squint, but a vertical heterophoria (small compensated angle of deviation as described in the ocular mechanics section above), this subtle tendency towards misalignment of visual axes may cause conflict between sensory and motor signals involved in controlling posture, which may contribute to the experience of non-specific chronic low back pain (Matheron & Kapoula, 2011). In a study looking at postural stability of patients with chronic low back pain and a vertical heterophoria, compared to healthy subjects with and without a heterophoria, Matheron and Kapoula (2011) found that although both groups with heterophoria had reduced postural stability, those with back pain had an increased variance of speed of postural sway. This suggests that the back pain patients were using their lower limbs to a greater extent to control their posture and were therefore expending greater energy to maintain upright stance. When the vertical heterophoria was corrected with a spectacle lens prism postural stability significantly improved. The clinical significance of this is that even small ocular-motor imbalance may contribute to chronic back pain.

As previously stated, people who have a squint are more likely to have reduced stereopsis. People with reduced stereopsis are less able to judge the position and height of objects in space, and these people are more cautious when stepping over obstacles. This is evidenced in a study, which found walking velocity and penultimate stride-length decreased in stereo-deficient subjects compared to normal subjects (Buckley et al., 2010). Therefore, reduced stereopsis could increase susceptibility to falls: the hesitant walking of the study subjects was to try to reduce this risk. In this situation, a relatively subtle degradation of visual input appears to upset the perception of the body in space.

Effect of neck pain on eye movement

Thus far, this article has explored the impact of ocular-motor disorders on musculoskeletal pain and postural stability. However, it is not just that oculomotor disorders can impact upon neck pain, but it appears that there may be a reciprocal link, whereby neck pain may impact upon eye movement. A number of studies have suggested that neck pain can impact postural stability (Treleaven, 2008a, 2008d; Treleaven et al., 2011; Vuillerme & Pinsault, 2009). Treleaven (2008a, 2008b) and Treleaven et al (2011) suggest that due to the high density of muscle spindles in the cervical spine, particularly in the upper regions, and their connections with vestibular and oculo-motor reflex control centres, neck pain can cause sensorimotor disturbance in these systems. This may be a cause of dizziness, which often occurs with neck pain, and can also cause subtle changes in the control of eye movements. They suggest that examination should routinely include tests of sensorimotor function, including cervical spine joint position sense, oculomotor control and postural stability. Where potential problems are found, specific sensorimotor exercises should be used to address postural instability and head and eye movement control (Treleaven, 2008a).

Conclusion

Neck and back pain are amongst the most common disorders presented to a musculoskeletal physiotherapist, but sometimes it can be difficult to establish an underlying cause for symptoms. The presence of squint can be one reason why patients may develop a torticollis, and possibly an associated scoliosis, which could contribute to the development of musculoskeletal pain. Although Physiotherapy may well be able to offer advice about ways to alleviate symptoms in the short term

in these cases, referral to an ophthalmic professional would be appropriate to address the underlying cause of the problem.

An understanding of the important interactions between the visual and vestibular systems and proprioception may also help clinicians to identify the potential causes and therefore potential treatment options for associated symptoms of chronic neck pain, such as dizziness and postural instability, which can often be difficult to manage. It appears that disturbance of any one of these systems can potentially alter the function of the other systems, however subtly, which may produce symptoms. For example, even quite subtle oculomotor dysfunction may cause disruption in the sensorimotor system, which could contribute to more general chronic pain conditions, so awareness of the importance of these interactions may offer alternative approaches to management, though this is an area where further research is needed.

It has become clear from the literature presented, that the integration of signals from the visual, vestibular and proprioceptive systems is very important for the normal functioning of postural mechanisms. The article has explored the impact of ocular-motor imbalance on head position and the potential consequences of musculoskeletal pain and / or postural imbalance. It is important for ophthalmic professions to understand the possible musculoskeletal consequences of squint, and hence be aware of the need to inform other health care professionals. Physiotherapists also need to be aware that the clinical aetiology of some pain and postural problems may be ocular. Therefore,

due to the complex nature of sensorimotor integration of signals from the visual, vestibular and musculoskeletal systems required for the attainment and maintenance of balance and postural stability, there appears to be potential for wider collaboration between rehabilitation professionals such as physiotherapists and ophthalmic professionals such as optometrists and orthoptists.

References

- Bellizzi, M., Rizzo, G., Bellizzi, G., Ranieri, M., Fanelli, M., Megna, G., & Procoli, U. (2011). Electronic baropodometry in patients affected by ocular torticollis. *Strabismus*, 19(1), 21-25.
- Bronstein, A. M. (1995). Visual vertigo syndrome: clinical and posturography findings. *Journal of Neurology, Neurosurgery and Psychiatry*, 59, 472-476.
- Buckley, J. G., Panesar, G. K., MacLeellan, M. J., Pacey, I. E., & Barrett, B. T. (2010). Changes to control of adaptive gait in individuals with long-standing reduced stereoacuity. *Investigative Ophthalmology & Visual Science*, 51(5), 2487-2495.
- Dietrich, D. E., & Slack, W. J. (1967). Scoliosis secondary to unilateral extraocular muscle paresis (ocular torticollis). *Radiology*, 88, 538-542.
- Guyton, A. C., & Hall, J. E. (2006). *Textbook of Medical Physiology* (11th ed.). Philadelphia: Elsevier.
- Hilton, A. F. (1980). Scoliosis and vertical ocular muscle paresis. *Australian Journal of Ophthalmology*, 8, 21-28.
- Kanski, J. J. (1994). *Clinical Ophthalmology* (3rd ed.). London: Butterworth-Heinemann Ltd.

- Lau, F. H. S., Fan, D. S. P., Sun, K. K. W., Yu, C. B. O., Wong, C. Y., & Lam, D. S. C. (2009). Residual torticollis in patients after strabismus surgery for congenital superior oblique palsy. *British Journal of Ophthalmology*, *93*(12), 1616-1619.
- Legrand, A., Bui-Quoc, E., Vacher, S. W., Ribot, J., Lebas, N., Milleret, C., & Bucci, M. P. (2011). Postural control in children with strabismus: Effect of eye surgery. *Neuroscience Letters*, *501*, 96-101.
- Lions, C., Bui-Quoc, E., & Bucci, M. P. (2013). Posture control in strabismic children versus non strabismic age-matched children. *Graefes Arch Clin Exp Ophthalmol*, *251*, 2219-2225.
- Matheron, E., & Kapoula, Z. (2011). Vertical Heterophoria and Postural Control in Nonspecific Low Back Pain. *PLoS ONE*, *6*(3). Retrieved from: <http://www.plosone.org/article/info%3Adoi%2F10.1371%2Fjournal.pone.0018110> doi:10.1371/journal.pone.0018110
- Morningstar, M. W., Pettibon, B. R., Schlappi, H., Schlappi, M., & Ireland, T. V. (2005). Reflex control of the spine and posture: a review of the literature from a chiropractic perspective. *Chiropractic and Osteopathy*, *13*(6). Retrieved from: <http://www.chiroandosteo.com/content/13/1/16> doi:10.1186/1746-1340-13-16
- Pickwell, D. (1984). *Binocular Vision Anomalies Investigation and Treatment*. London: Butterworths.
- Poulain, I., & Giraudet, G. (2008). Age-related changes of visual contribution in postural control. *Gait & Posture*, *27*, 1-7.
- Przekoracka-Krawczyk, A., Nawrot, P., Czainska, M., & Krzysztof, P. M. (2014). Impaired body balance control in adults with strabismus. *Vision Research*, *98*, 35-45.
- Sawle, G. (1996). Visual Vertigo. *The Lancet*, *347*(April 13), 986-987.
- Shapiro, J. (1994). Relation between vertical facial asymmetry and postural changes of the spine and ancillary muscles. *Optometry and Vision Science*, *71*(8), 529-538.
- Treleaven, J. (2008a). Sensorimotor disturbances in neck disorders affecting postural stability, head and eye movement control. *Manual Therapy*, *13*, 2-11.
- Treleaven, J. (2008d). Sensorimotor disturbances in neck disorders affecting postural stability, head and eye movement control - part 2: case studies. *Manual Therapy*, *13*, 266-275.
- Treleaven, J., Clamaron-Cheers, C., & Jull, G. (2011). Does the region of pain influence the presence of sensorimotor disturbances in neck pain disorders? *Manual Therapy*, *16*, 636-640.
- Vuillerme, N., & Pinsault, N. (2009). Experimental neck muscle pain impairs standing balance in humans. *Exp Brain Res*, *192*, 723-729.
- Waugh, A., & Grant, A. (2014). *Ross and Wilson Anatomy and Physiology in Health and Illness* (12th ed.). Edinburgh: Elsevier.
- Wright, K. W. (2007). Torticollis, Nystagmus and Incomitant Strabismus *Color Atlas of Strabismus Surgery*. New York: Springer.

