

Northumbria Research Link

Citation: Valkering, Kars, Rajeev, Aysha, Caplan, Nick, Tuinebreijer, Wim and Kader, Deary (2016) An evaluation of the effectiveness of medial patellofemoral ligament reconstruction using an anatomical tunnel site. *Knee Surgery, Sports Traumatology, Arthroscopy*. ISSN 0942-2056

Published by: Springer

URL: <http://dx.doi.org/10.1007/s00167-016-4292-x> <<http://dx.doi.org/10.1007/s00167-016-4292-x>>

This version was downloaded from Northumbria Research Link:
<http://nrl.northumbria.ac.uk/27647/>

Northumbria University has developed Northumbria Research Link (NRL) to enable users to access the University's research output. Copyright © and moral rights for items on NRL are retained by the individual author(s) and/or other copyright owners. Single copies of full items can be reproduced, displayed or performed, and given to third parties in any format or medium for personal research or study, educational, or not-for-profit purposes without prior permission or charge, provided the authors, title and full bibliographic details are given, as well as a hyperlink and/or URL to the original metadata page. The content must not be changed in any way. Full items must not be sold commercially in any format or medium without formal permission of the copyright holder. The full policy is available online: <http://nrl.northumbria.ac.uk/policies.html>

This document may differ from the final, published version of the research and has been made available online in accordance with publisher policies. To read and/or cite from the published version of the research, please visit the publisher's website (a subscription may be required.)

www.northumbria.ac.uk/nrl



An evaluation of the effectiveness of medial patellofemoral ligament reconstruction using an anatomical tunnel site

Kars P Valkering¹, Aysha Rajeev¹, Nick Caplan², Wim E Tuinebreijer³, Deary F Kader^{1,2,4}

- 1 Department of Trauma and Orthopaedics, Queen Elizabeth Hospital, Gateshead, United Kingdom
- 2 Faculty of Health and Life Sciences, Northumbria University, Newcastle upon Tyne, United Kingdom
- 3 Department of General Surgery, Red Cross Hospital, Beverwijk, the Netherlands
- 4 Orthopaedics, Nuffield Hospital, Newcastle upon Tyne, United Kingdom

Corresponding author:

Professor Deary Kader

Consultant Orthopaedic and Trauma Surgeon

Knee Surgeon Arthroscopy, Arthroplasty and Sports Injury

Nuffield Hospital, Newcastle upon Tyne

United Kingdom, NE2 1JP

deary.kader@gmail.com

Abstract

Purpose

Medial patellofemoral ligament (MPFL) reconstruction for recurrent patellar instability has gained popularity and anatomical and biomechanical studies have recently altered our operative techniques. The aim of this study was to report the clinical outcome of this new anatomical MPFL reconstructive technique and investigate whether correlating factors could be identified.

Methods

Between 2009 and 2012, a total of 31 consecutive patients underwent MPFL reconstruction using an autologous gracilis graft and anatomical tunnel placement. Pre- and post-operative data were collected as a part of routine clinical practice. The preoperative assessment included a rotational profile CT scan of the lower extremity according to the Lyon protocol with TT-TG distance measurement. Outcomes were evaluated with the Kujala and Norwich patella instability (NPI) scores preoperatively and at follow-up (1.5-5.1 years).

Results

A significant improvement of both the Kujala ($p < 0.001$) and NPI ($p = 0.012$) scores was recorded. A medium and large negative correlation were found between TT-TG distance and Kujala score improvement ($\rho = -0.48$, $p = 0.020$) and NPI score improvement ($\rho = -0.83$, $p = 0.042$), respectively. Multiple regression analysis identified TT-TG distance, Beighton score and BMI as factors explaining the variance of Kujala score improvement.

Conclusion

Anatomical MPFL reconstruction with the gracilis autograft for patellar instability resulted in good outcome. This underlines the importance of anatomical tunnel placement in MPFL reconstruction. With a precise preoperative work-up, factors can be identified that may guide selecting the optimal operative strategy and improve counseling of the patient.

Level of Evidence

Case

series,

IV

Introduction

The medial patellofemoral ligament (MPFL) is recognized to play an important role in patellar stability and is injured in nearly every patellar dislocation [6]. Medial patellofemoral ligament transection results in significant alterations to patellofemoral joint (PFJ) tracking and contact pressures, which may affect articular cartilage health [39]. The overall recurrence rate after primary patellar dislocation is 17% and this percentage increases to 49% for patients with a history of instability [12].

The most common contributing factors to recurrent patellar instability include bony abnormalities, such as trochlear dysplasia [9,45], patella alta [28], increased tibial tubercle to trochlear groove (TT-TG) distance [31], and axial alignment deformities [13,18].

Since Ellera Gomes stressed the importance of the reconstruction of the MPFL in 1992 [10], it has been adopted by many surgeons [43]. A variety of techniques, graft options and fixation methods have been described [4,25,44]. With an increasing number of medical centers performing MPFL reconstruction, the functional outcomes remain favorable as complication and failure rates are improving [43].

Isometry of the reconstructed ligament is considered to be a prerequisite to a good outcome and an anatomical placement of the graft is the key to accomplish this [19]. Schöttle et al proposed an anatomical femoral attachment site to be used in MPFL reconstruction that was based on a descriptive laboratory study [37]. However, McCarthy et al reported that Schöttle's point does not correlate with functional

outcome [26]. Recently, cadaveric studies have provided new insights in anatomical positioning and graft tension [14,32,34,40,41]. These studies proposed that the optimum anatomical femoral attachment site is situated at the confluence of the posterior femoral cortex and Blumensaat's line, and posterior to the line extending from the posterior cortex of the femur (Figure 1) – more than 5 mm distal and posterior to the point proposed by Schöttle et al [36,37]. A previous cadaveric study showed that a 5mm non-anatomic femoral attachment, either proximally or distally, causes a significant increase in medial contact pressures and medial patellar tilt in flexion and extension respectively [41].

Whilst this new anatomical femoral attachment site has been reported from cadaver studies, no studies have evaluated the clinical outcome *in vivo*. The aim of this study, therefore, was to report the clinical outcome of this new anatomical MPFL reconstructive technique and investigate if correlating patient characteristics and preoperative CT measurements could be identified.

Materials and Methods

A consecutive cohort of 31 patients (21 female, 10 male) reporting to a specialist patella clinic for recurrent patella instability received reconstructive surgery of their MPFL between April 2009 and November 2012. The mean (\pm SD) age of the patients was 23.9 ± 6.9 years at the time of their attendance at the clinic.

Anatomic Medial Patellofemoral Ligament Reconstruction Technique and Perioperative care

Each patient was positioned supine with a semi flexed knee at 60°-70°. During surgery a tourniquet was used. All incisions were in a longitudinal orientation. The gracilis tendon was harvested from the patient's ipsilateral side. At the patella a rongeur was used to create a 20 mm long and 5 mm wide trough in the proximal 2/3 of the medial border of the patella. Two Mitek GII® Titanium Anchors (DePuy Synthes, Raynham, Massachusetts) with Ethibond® Sutures (Ethicon Inc, Somerville, New Jersey) were inserted at the proximal and distal ends of the groove. The graft was positioned and sutured at the midlength in the patellar groove.

The anatomic center of the femoral attachment of the MPFL was identified at the midpoint between the medial epicondyle and the adductor tubercle. A lateral x-ray was used to confirm the identification of the femoral MPFL attachment, i.e. at the confluence of the posterior femoral cortex and Blumensaat's line and posterior to the line extending from the posterior cortex of the femur. The femoral tunnel was drilled using a 2.4 mm drill pin from medial to lateral. To double check the isometric positioning of the graft the two ends were wrapped around the drill pin to assess the graft excursion while the knee was moved through a full range of motion. The two ends of the graft were then stitched together with Ethibond® and the femoral tunnel was enlarged using a 5-6 mm reamer to a depth of 30 mm. The ends of the graft were pulled between the second and third layers of the medial retinaculum, and the sutures were pulled out laterally through the femoral tunnel. A tension of 2 N was applied to the graft at a 60°-70° knee flexion angle before fixation in the femoral tunnel using a 7x25 mm metal interference screw [40]. The wounds were closed in layers, without the use of drains and a compressive bandage was applied.

Postoperatively, a full range of motion was allowed without the use of a brace and full weightbearing was allowed as well.

Outpatient evaluation

Before surgery, each patient underwent a full clinical examination which included the Kujala Score assessment [24,29], as well as plain anteroposterior and lateral x-ray of the knee and CT investigation of the anatomy of the knee according to the CT Lyon protocol with TT-TG measurement [15], assessment of trochlear dysplasia (Dejour classification) and boss height (TBH) and patellar height (Caton-Deschamps index). The CT investigation was conducted by a single consultant radiologist that has previously shown excellent repeatability [7]. The recorded patient characteristics included height, mass, body mass index (BMI) and Beighton score [5]. Since 2011, the Norwich Patella Instability (NPI) score has been incorporated into our assessment. The validation of the NPI score has recently been published [38]. Each patient attended follow-up appointments at which they completed the Kujala and NPI score outcome measures.

Pre- and post-operative data were collected as a part of routine clinical practice. Full ethical approval was not required as this was a service evaluation. The study was approved as an audit by the Gateshead Health NHS Foundation Trust research committee.

Statistical analysis:

All variables were summarized with standard descriptive statistics, including mean, median, standard deviation and range. A paired samples t-test was suitable to

calculate differences in the Kujala score between pre- and post-MPFL reconstruction considering the central limit theorem [22]. Since the postoperative data showed a skewed distribution and a low number of comparable data for the NPI score, a non-parametric Wilcoxon matched pairs test was chosen to assess this questionnaire. The NPI data are presented as medians and interquartile range (IQR) [30]. Spearman's correlation analysis was performed on both the Kujala and NPI score improvements versus the TT-TG measurements. Small, medium and large effect sizes are ρ (rho) values of 0.1-0.3, 0.3-0.5 and > 0.5 , respectively [8]. A multiple regression analysis (MRA) was performed on the improvement of the Kujala score to identify factors explaining spreading variance. The significance level in all analyses was 95% (two-tailed). All statistical analyses were conducted using IBM SPSS version 22.

Results

Table 1 reports the patient characteristics and preoperative CT measurements of the cohort. The mean (\pm SD) final outpatient evaluation was 3.1 ± 1.2 years post-surgery. A normal trochlea was diagnosed in 15 (48%), Dejour type A in 3 (10%), Dejour type C in 9 (29%) and Dejour type D in 4 (13%) cases.

One patient (type C trochlear dysplasia, TBH 3.6mm, Caton-Deschamps index 0.98, TT-TG 16mm, BMI 29.7 and Beighton score 0) suffered from subsequent traumatic dislocation of the patella and needed revision surgery and one patient needed

removal of a painful proud femoral interference screw. There were no postoperative infections or fractures.

The pre- and post-operative Kujala and NPI scores as well as the improvement of both scores are reported in table 2. The mean Kujala score significantly increased following reconstruction of the MPFL from 53.3 (SD 19.3) to 80.9 (SD 6.1) ($p < 0.001$, CI -35.4 to -19.6). The subset of patients with both a pre- and post-operative NPI score assessment also displayed a significant improvement from a median 33.2 (IQR 7.71) to 0.8 (IQR 0.38) ($p = 0.012$).

The female subset of the population had a non-significant higher Kujala score improvement, which was most likely explained by the significant difference found for the TT-TG between females (mean 16.0; SD 3.6) and males (mean 22.1; SD 3.8) ($p = 0.001$, CI -9.32 to -2.90).

Spearman's correlation analysis between the postoperative improvement of both outcome measures versus TT-TG distance showed a correlation coefficient ρ (rho) - 0.48 ($p = 0.020$) for the Kujala score (Figure 2) and -0.83 ($p = 0.042$) for the NPI score (Figure 3). According to our classification system these were medium and large negative correlations of Kujala score improvement and NPI score improvement, respectively. The negative values indicate that a higher TT-TG distance resulted in a smaller improvement in outcome measure score. No significant correlations were found between Dejour classification, TBH or Caton-Deschamps index and Kujala score improvement.

In the MRA model based on the Kujala score improvement, 30% of the variance was explained by the TT-TG, 56% by the combination of TT-TG and Beighton score and 68% by the combination of TT-TG, Beighton score and BMI. In this model a low TT-TG, low Beighton score and a high BMI predicted a higher Kujala score improvement (Table 3). Body mass index correlated negatively with the preoperative Kujala score ($\rho=-0.26$) and positively with the postoperative Kujala score ($\rho=0.16$), although neither of these were significant.

Discussion

The most important finding of the present study was a significant clinical improvement of a new anatomical MPFL reconstructive technique using a gracilis autograft. A significant improvement in both Kujala and NPI scores was recorded. A multiple regression analysis identified a low TT-TG distance, low Beighton score and high BMI as positive predictors of Kujala score improvement.

A variety of different grafts and fixation techniques for MPFL reconstruction have been described previously [43]. What they have in common is the ability to significantly improve outcome measured with the Kujala score. Stupay et al. compared older and newer publications and could not detect a significant difference between their mean postoperative Kujala scores of 89.4 (SD 4.9) and 89.0 (SD 3.7), respectively, despite MPFL reconstruction becoming a more common procedure [43].

Recently, two studies reported very good results of the biggest MPFL cohorts up to date.[11,20] Enderlein et al used the gracilis autograft in a series of 240 MPFL reconstructions, but used a kinematic method of positioning the femoral tunnel [11]. In contrast, Howells et al used an anatomical femoral tunnel position according to Schöttle et al [36,37] in a series of 219 procedures and used the semitendinosus tendon [20]. Both studies either excluded patients with an increased TT-TG or supplemented the MPFL reconstruction with a medial tibial tuberosity transfer. The mean postoperative Kujala scores in this study were in accordance with the studies of Enderlein et al [11] and Howells et al [20] and are, therefore, slightly lower than the average results as described by Stupay et al [43]. An explanation for this might be the fact that in our cohort we included patients with a relatively high BMI (mean 27.8, SD 6.3) and TT-TG distance (mean 18.3 mm, SD 4.7 mm). Both factors correlated with a lower outcome in our series. The outcome of MPFL reconstruction with gracilis autograft using Schöttle's reference has been described in children [27], adolescents [46] and adults [33]. Although these studies reported higher postoperative Kujala scores compared to our results, our study had the lowest preoperative Kujala score. In addition, the mean Kujala score improvement in our study (27.5 points) was higher than the mean Kujala score improvement of Nelitz et al. [27] (19.9 points) and Wagner et al. [46] (17 points). Schöttle reported mean Kujala score improvements of 30.7 and 32 with the use of respectively semitendinosus [33] and gracilis autografts [35].

Interestingly, the mean (\pm SD) TT-TG distance of the men in our study was significantly higher compared to the women, and measured 22.1 ± 3.8 mm versus 16.0 ± 3.6 mm respectively. According to Dejour et al. a TT-TG distance greater than

or equal to 20 mm has been defined as pathological [9]. This may explain the non-significant higher Kujala score improvement of the female subset of the population.

The TT-TG distance has been proposed to radiographically assess the alignment of the trochlear groove to the tibial tuberosity [9,16]. Although the TT-TG distance alone may not be a decisive element in establishing therapeutic choices for patellar instability [7], an increase in TT-TG distance has been reported in patients with patellar instability [1,2]. The effects of TT-TG distance on patellofemoral kinematics, contact kinematics and stability have been shown in a controlled laboratory study; progressive TT lateralization elevated lateral contact pressures, increased lateral patellar tracking, and reduced patellar stability [42]. The detrimental effect of an increased TT-TG distance on patellar biomechanics might explain the negative correlation with Kujala score improvement in this study.

The positive correlation between BMI and improvement of the Kujala score after MPFL reconstruction could be explained by the fact that patients with a higher BMI had a lower Kujala score preoperatively and, therefore, had a greater potential to improve. This finding is in accordance with a study by Barbat-Artigas et al., which showed a significant association between muscle quality (defined by right knee maximum extension strength), physical function (defined by 4 physical function tests) and BMI [3]. Enderlein et al. also identified obesity to be a predictor of poor subjective outcome after MPFL reconstruction [11]. We hypothesize that patients with a higher BMI are more disabled by instability due to lack of stabilizing muscle support.

The negative correlation between Beighton score and Kujala score improvement found in this study concord with a study by Howells and Eldridge [21]. In their case-

control study on the outcome of MPFL reconstruction they found a significant difference between the outcomes of a cohort with hypermobility (Beighton score ≥ 6) and controls (Beighton score < 4). A possible explanation for this effect might be the poor knee proprioception seen in hypermobile patients [17]. In our opinion, joint hypermobility is not a contraindication to MPFL reconstruction, although caution is recommended in managing the expectations of patients with hypermobility.

A limitation to this study was the relatively small number of patients. A MRA is normally for use in larger samples, however, the three predictors TT-TG distance, Beighton score and BMI had a large enough effect size to test the overall regression model [23]. Finally, post-op imaging to evaluate tunnel positioning was not included. To the best of our knowledge, this study reports the results with the longest follow-up for anatomical MPFL reconstruction using the gracilis autograft. All patients were operated in a uniform way by a single surgeon with a biomechanically proven anatomical technique. An unknown factor, however, with regards to the development of this anatomical technique is the fact that the used cadaveric specimens may not have been comparable to a population of patients with patellofemoral instability.

A suggestion for further research is a randomized controlled trial comparing the functional outcome of MPFL reconstruction with the use of either Schöttle's point or our anatomical point of the femoral origin. In addition, further research is needed to confirm the appropriateness of a medializing tibial tubercle osteotomy in combination with MPFL reconstruction, and to define the exact TT-TG distance that warrants the addition of a tibial tubercle osteotomy.

Conclusion

Anatomical MPFL reconstruction with the gracilis autograft for patellar instability resulted in good outcome.

A significant improvement in both Kujala and NPI scores was recorded. Factors correlating with a higher Kujala score improvement included a low TT-TG distance, a low Beighton score and a high BMI.

With a precise preoperative work-up, these factors can be identified that may guide selecting the optimal operative strategy and improve counseling of the patient.

Conflict of interest

The authors declare that they have no conflict of interest.

Reference List

1. Balcarek P, Jung K, Ammon J, Walde TA, Frosch S, Schuttrumpf JP, Sturmer KM, Frosch KH (2010) Anatomy of lateral patellar instability: trochlear dysplasia and tibial tubercle-trochlear groove distance is more pronounced in women who dislocate the patella. *Am J Sports Med* 38:2320-2327
2. Balcarek P, Jung K, Frosch KH, Sturmer KM (2011) Value of the tibial tuberosity-trochlear groove distance in patellar instability in the young athlete. *Am J Sports Med* 39:1756-1761
3. Barbat-Artigas S, Pion CH, Leduc-Gaudet JP, Rolland Y, Aubertin-Leheudre M (2014) Exploring the role of muscle mass, obesity, and age in the relationship between muscle quality and physical function. *J Am Med Dir Assoc* 15:303-320
4. Becher C, Kley K, Lobenhoffer P, Ezechieli M, Smith T, Ostermeier S (2014) Dynamic versus static reconstruction of the medial patellofemoral ligament for recurrent lateral patellar dislocation. *Knee Surg Sports Traumatol Arthrosc* 22:2452-2457
5. Beighton P, Solomon L, Soskolne CL (1973) Articular mobility in an African population. *Ann Rheum Dis* 32:413-418
6. Burks RT, Desio SM, Bachus KN, Tyson L, Springer K (1998) Biomechanical evaluation of lateral patellar dislocations. *Am J Knee Surg* 11:24-31

7. Caplan N, Lees D, Newby M, Ewen A, Jackson R, St Clair GA, Kader D (2014) Is tibial tuberosity-trochlear groove distance an appropriate measure for the identification of knees with patellar instability? *Knee Surg Sports Traumatol Arthrosc* 22:2377-2381
8. Cohen J (1988) *Statistical power analysis for the behavioral sciences*, Second edn. Hillsdale, New Jersey.
9. Dejour H, Walch G, Nove-Josserand L, Guier C (1994) Factors of patellar instability: an anatomic radiographic study. *Knee Surg Sports Traumatol Arthrosc* 2:19-26
10. Ellera Gomes JL (1992) Medial patellofemoral ligament reconstruction for recurrent dislocation of the patella: a preliminary report. *Arthroscopy* 8:335-340
11. Enderlein D, Nielsen T, Christiansen SE, Fauno P, Lind M (2014) Clinical outcome after reconstruction of the medial patellofemoral ligament in patients with recurrent patella instability. *Knee Surg Sports Traumatol Arthrosc* 22:2458-2464
12. Fithian DC, Paxton EW, Stone ML, Silva P, Davis DK, Elias DA, White LM (2004) Epidemiology and natural history of acute patellar dislocation. *Am J Sports Med* 32:1114-1121
13. Foulleron N, Marchetti E, Autissier G, Gougeon F, Migaud H, Girard J (2010) Proximal tibial derotation osteotomy for torsional tibial deformities generating patello-femoral disorders. *Orthop Traumatol Surg Res* 96:785-792

14. Fujino K, Tajima G, Yan J, Kamei Y, Maruyama M, Takeda S, Kikuchi S, Shimamura T (2015) Morphology of the femoral insertion site of the medial patellofemoral ligament. *Knee Surg Sports Traumatol Arthrosc* 23:998-1003
15. Galland O, Walch G, Dejour H, Carret JP (1990) An anatomical and radiological study of the femoropatellar articulation. *Surg Radiol Anat* 12:119-125
16. Goutallier D, Bernageau J, Lecudonnec B (1978) The measurement of the tibial tuberosity. Patella groove distanced technique and results. *Rev Chir Orthop Reparatrice Appar Mot* 64:423-428
17. Hall MG, Ferrell WR, Sturrock RD, Hamblen DL, Baxendale RH (1995) The effect of the hypermobility syndrome on knee joint proprioception. *Br J Rheumatol* 34:121-125
18. Hinterwimmer S, Rosenstiel N, Lenich A, Waldt S, Imhoff AB (2012) Femoral osteotomy for patellofemoral instability. *Unfallchirurg* 115:410-416
19. Hopper GP, Leach WJ, Rooney BP, Walker CR, Blyth MJ (2014) Does degree of trochlear dysplasia and position of femoral tunnel influence outcome after medial patellofemoral ligament reconstruction? *Am J Sports Med* 42:716-722
20. Howells NR, Barnett AJ, Ahearn N, Ansari A, Eldridge JD (2012) Medial patellofemoral ligament reconstruction: a prospective outcome assessment of a large single centre series. *J Bone Joint Surg Br* 94:1202-1208

21. Howells NR and Eldridge JD (2012) Medial patellofemoral ligament reconstruction for patellar instability in patients with hypermobility: a case control study. *J Bone Joint Surg Br* 94:1655-1659
22. Indrayan, A (2008) *Medical biostatistics*, Second edn. Chapman & Hall/CRC, Taylor & Francis Group, Boca Raton London New York.
23. Katz, M. H. (2006) *Multivariable analysis. A practical guide for clinicians*, Second edn. Cambridge University Press, Cambridge.
24. Kujala UM, Jaakkola LH, Koskinen SK, Taimela S, Hurme M, Nelimarkka O (1993) Scoring of patellofemoral disorders. *Arthroscopy* 9:159-163
25. Lorbach O, Hauptert A, Efe T, Pizanis A, Weyers I, Kohn D, Kieb M (2016) Biomechanical evaluation of MPFL reconstructions: differences in dynamic contact pressure between gracilis and fascia lata graft. *Knee Surg Sports Traumatol Arthrosc*
26. McCarthy M, Ridley TJ, Bollier M, Wolf B, Albright J, Amendola A (2013) Femoral tunnel placement in medial patellofemoral ligament reconstruction. *Iowa Orthop J* 33:58-63
27. Nelitz M, Dreyhaupt J, Reichel H, Woelfle J, Lippacher S (2013) Anatomic reconstruction of the medial patellofemoral ligament in children and adolescents with open growth plates: surgical technique and clinical outcome. *Am J Sports Med* 41:58-63
28. Neyret P, Robinson AH, Le CB, Lapra C, Chambat P (2002) Patellar tendon length - the factor in patellar instability? *Knee* 9:3-6

29. Paxton EW, Fithian DC, Stone ML, Silva P (2003) The reliability and validity of knee-specific and general health instruments in assessing acute patellar dislocation outcomes. *Am J Sports Med* 31:487-492
30. Peacock, J. and Kerry, S. (2007) Presenting medical statistics from proposal to publication. A step-by-step guide, First edn. Oxford University Press, Oxford.
31. Pennock AT, Alam M, Bastrom T (2014) Variation in tibial tubercle-trochlear groove measurement as a function of age, sex, size, and patellar instability. *Am J Sports Med* 42:389-393
32. Placella G, Tei MM, Sebastiani E, Criscenti G, Speziali A, Mazzola C, Georgoulis A, Cerulli G (2014) Shape and size of the medial patellofemoral ligament for the best surgical reconstruction: a human cadaveric study. *Knee Surg Sports Traumatol Arthrosc* 22:2327-2333
33. Quirbach S, Smekal V, Rosenberger RE, El AR, Schottle PB (2012) [Anatomical double-bundle reconstruction of the medial patellofemoral ligament with a gracilis autograft]. *Oper Orthop Traumatol* 24:131-139
34. Redfern J, Kamath G, Burks R (2010) Anatomical confirmation of the use of radiographic landmarks in medial patellofemoral ligament reconstruction. *Am J Sports Med* 38:293-297
35. Schottle PB, Fucentese SF, Romero J (2005) Clinical and radiological outcome of medial patellofemoral ligament reconstruction with a semitendinosus autograft for patella instability. *Knee Surg Sports Traumatol Arthrosc* 13:516-521

36. Schöttle PB, Romero J, Schmeling A, Weiler A (2008) Technical note: anatomical reconstruction of the medial patellofemoral ligament using a free gracilis autograft. *Arch Orthop Trauma Surg* 128:479-484
37. Schöttle PB, Schmeling A, Rosenstiel N, Weiler A (2007) Radiographic landmarks for femoral tunnel placement in medial patellofemoral ligament reconstruction. *Am J Sports Med* 35:801-804
38. Smith TO, Donell ST, Clark A, Chester R, Cross J, Kader DF, Arendt EA (2014) The development, validation and internal consistency of the Norwich Patellar Instability (NPI) score. *Knee Surg Sports Traumatol Arthrosc* 22:324-335
39. Stephen JM, Kader D, Lumpaopong P, Deehan DJ, Amis AA (2013) Sectioning the medial patellofemoral ligament alters patellofemoral joint kinematics and contact mechanics. *J Orthop Res* 31:1423-1429
40. Stephen JM, Kader D, Lumpaopong P, Deehan DJ, Amis AA (2014) The effect of femoral tunnel position and graft tension on patellar contact mechanics and kinematics after medial patellofemoral ligament reconstruction. *Am J Sports Med* 42:364-372
41. Stephen JM, Lumpaopong P, Deehan DJ, Kader D, Amis AA (2012) The medial patellofemoral ligament: location of femoral attachment and length change patterns resulting from anatomic and nonanatomic attachments. *Am J Sports Med* 40:1871-1879
42. Stephen JM, Lumpaopong P, Dodds AL, Williams A, Amis AA (2015) The effect of tibial tuberosity medialization and lateralization on

patellofemoral joint kinematics, contact mechanics, and stability. *Am J Sports Med* 43:186-194

43. Stupay KL, Swart E, Shubin Stein BE (2015) Widespread Implementation of Medial Patellofemoral Ligament Reconstruction for Recurrent Patellar Instability Maintains Functional Outcomes at Midterm to Long-Term Follow-up While Decreasing Complication Rates: A Systematic Review. *Arthroscopy* 31:1372-1380
44. Torabi M, Wo S, Vyas D, Costello J (2015) MRI evaluation and complications of medial patellofemoral ligament reconstruction. *Clin Imaging* 39:116-127
45. Van Haver A., De Roo K., De Beule M., Labey L, De Baets P., Dejour D, Claessens T, Verdonk P (2015) The Effect of Trochlear Dysplasia on Patellofemoral Biomechanics: A Cadaveric Study With Simulated Trochlear Deformities. *Am J Sports Med* 43:1354-1361
46. Wagner D, Pfalzer F, Hingelbaum S, Huth J, Mauch F, Bauer G (2013) The influence of risk factors on clinical outcomes following anatomical medial patellofemoral ligament (MPFL) reconstruction using the gracilis tendon. *Knee Surg Sports Traumatol Arthrosc* 21:318-324

Tables and Figures

Table 1. Preoperative patient characteristics

Table 2. Pre and postoperative Kujala and Norwich Patella Instability scores

Table 3. Linear regression analysis, with different potential predictive factors: TT-TG distance, Beighton score and BMI with Kujala score improvement as dependent variable.

Figure 1. Diagram of the distal femur demonstrating the anatomic positioning of the femoral tunnel (from the senior author's dissection) in comparison with Schöttle's point. Line 1 indicates the posterior femoral cortex, line 2 is perpendicular to line 1 at the level of the posterior femoral condyle, line 3 is perpendicular to line 1 at the level of Blumensaat's line, the black dot indicates Schöttle's point and the orange dot indicates the anatomical femoral insertion of the MPFL.

Figure 2. Kujala score improvement vs. TT-TG

Figure 3. Norwich Patella Instability score improvement vs. TT-TG

Table 1. Preoperative patient characteristics

	M	SD	Minimum	Maximum
Age	23.9	6.9	14	43
Height	170.7	11.0	150	190
Weight	81.7	22.3	52.8	124
BMI	27.8	6.3	18.1	44.5
Beighton score	2.1	2.2	0	7
TT-TG	18.3	4.7	10	28
Caton-Deschamps index	1.1	0.2	0.7	1.7
Trochlear Boss Height	3.2	1.3	1.2	6.1

M=mean; SD=standard deviation; BMI=body mass index; TT-TG=tibial tubercle trochlear groove distance

Table 2. Pre and postoperative Kujala and Norwich Patella Instability scores

	M	SD	Minimum	Maximum
Kujala score preoperative	53.3	19.3	23	94
Kujala score postoperative	80.9	6.1	58	87
Kujala score improvement	27.5	19.9	-12	59
NPI score preoperative	33.3	19.3	7	71
NPI score postoperative	3.7	9.2	0	38
NPI score improvement	28.2	22.3	0	70

NPI= Norwich Patella Instability; M=mean; SD=standard deviation

Table 3. Linear regression analysis, with different potential predictive factors: TT-TG distance, Beighton score and BMI with Kujala score improvement as dependent variable.

Parameter	Regression coefficient	95% Confidence interval		Significance
		Lower	Upper	
TT-TG	-2.5	-3.6	-1.3	<0.001
Beighton score	-4.1	-6.5	-1.8	0.002
BMI	1.3	0.3	2.4	0.017

BMI=body mass index; TT-TG=tibial tubercle to trochlear groove

Figure 1

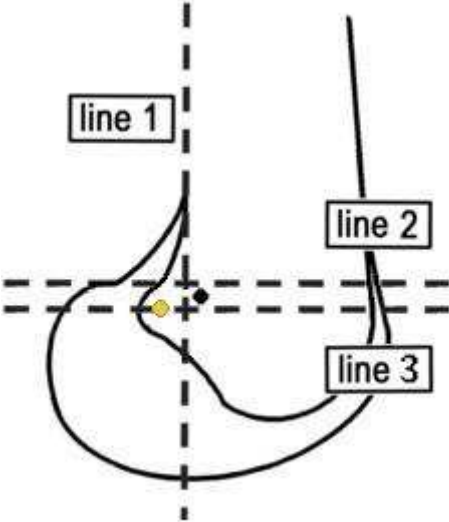


Figure 2. Kujala score improvement vs. TT-TG

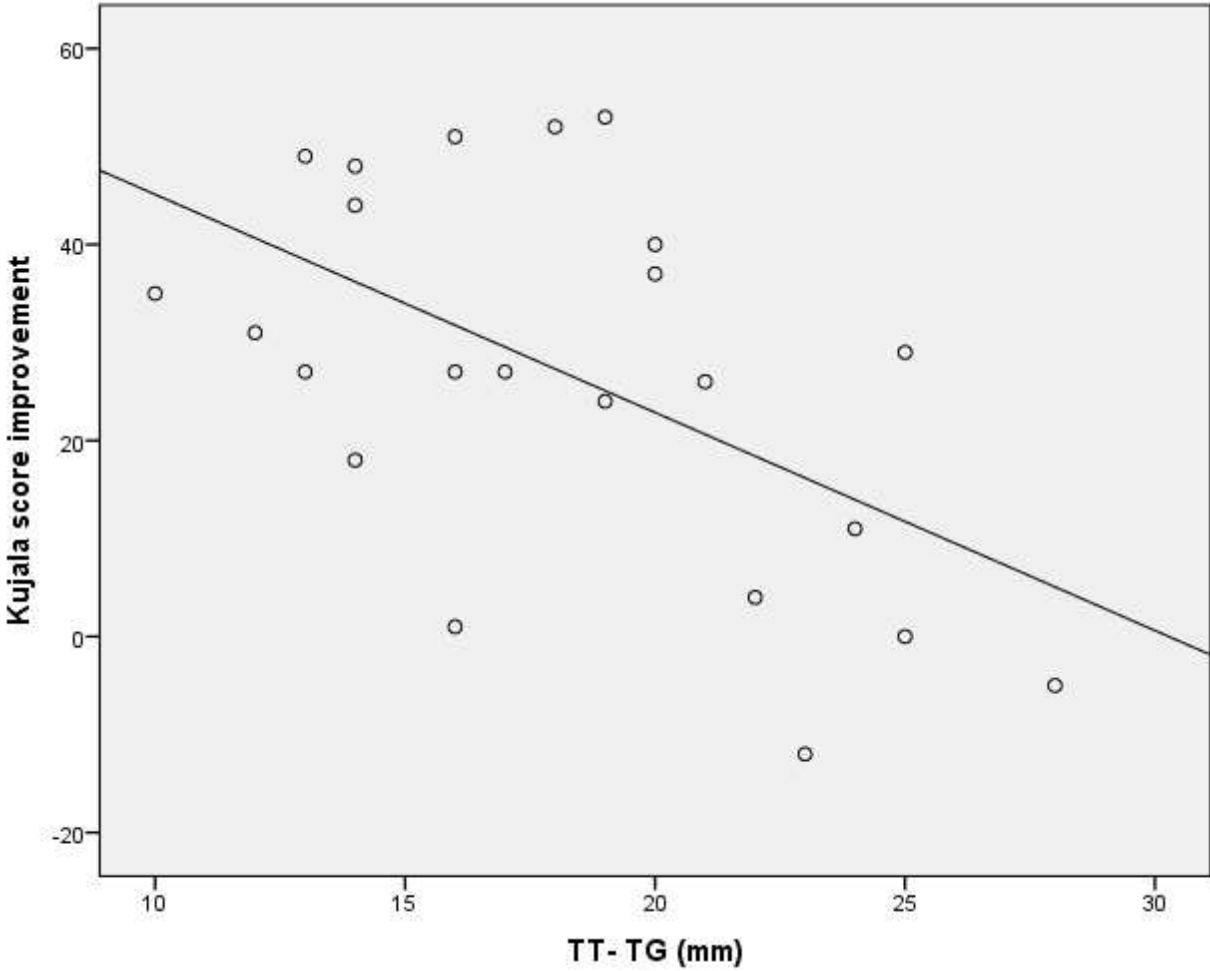


Figure 3. Norwich Patella Instability score improvement vs. TT-TG

