

Northumbria Research Link

Citation: Elson, David, Jones, S., Caplan, Nick, St Clair Gibson, Alan, Stewart, Su and Kader, Deiry (2013) Clinically insignificant association between anterior knee pain and patellofemoral lesions which are found incidentally. *The Knee*, 20 (6). pp. 471-475. ISSN 0968-0160

Published by: Elsevier

URL: <http://dx.doi.org/10.1016/j.knee.2013.02.002>
<<http://dx.doi.org/10.1016/j.knee.2013.02.002>>

This version was downloaded from Northumbria Research Link:
<http://nrl.northumbria.ac.uk/11151/>

Northumbria University has developed Northumbria Research Link (NRL) to enable users to access the University's research output. Copyright © and moral rights for items on NRL are retained by the individual author(s) and/or other copyright owners. Single copies of full items can be reproduced, displayed or performed, and given to third parties in any format or medium for personal research or study, educational, or not-for-profit purposes without prior permission or charge, provided the authors, title and full bibliographic details are given, as well as a hyperlink and/or URL to the original metadata page. The content must not be changed in any way. Full items must not be sold commercially in any format or medium without formal permission of the copyright holder. The full policy is available online: <http://nrl.northumbria.ac.uk/policies.html>

This document may differ from the final, published version of the research and has been made available online in accordance with publisher policies. To read and/or cite from the published version of the research, please visit the publisher's website (a subscription may be required.)

www.northumbria.ac.uk/nrl



Clinically insignificant association between anterior knee pain and patellofemoral lesions which are found incidentally.

¹Elson, D., ¹Jones, S., ²Caplan, N., ²St Clair Gibson, A., ²Stewart, S. & ^{1,2}Kader, D.

- 1 Queen Elizabeth Hospital, Gateshead, Tyne and Wear, United Kingdom
- 2 Faculty of Health and Life Sciences, Northumbria University, Newcastle upon Tyne, United Kingdom

Abstract

Patellofemoral chondral lesions are frequently identified incidentally during the arthroscopic treatment of other knee pathologies. A role has been described for arthroscopic debridement of such lesions when symptoms are known to originate from pathology of the patellofemoral joint. However, it remains unclear how to manage lesions which are found incidentally whilst tackling other pathologies. The purpose of this study was to establish the strength of association between anterior knee pain and patellofemoral lesions identified incidentally in a typical arthroscopic population.

A consecutive series of patients undergoing arthroscopy for a range of standard indications formed the basis of this cross section study. We excluded those with patellofemoral conditions in order to identify patellofemoral lesions which were solely incidental. Pre-operative assessments were performed on 64 patients, where anterior knee pain was sought by three methods: an annotated photographic knee pain map (PKPM), patient indication with one finger and by palpated tenderness. A single surgeon, who was blinded to previous recordings, performed standard arthroscopies and recorded patellofemoral lesions. Statistical correlations were performed to identify the association magnitude. Associations were identified between incidental patellofemoral lesions and tenderness palpated on the medial patella ($P=0.007$, $\chi^2=0.32$) and the quadriceps tendon ($P=0.029$, $\chi^2=0.26$), but these associations were at best fair, which **could be** interpreted as clinically insignificant. **In which case** incidental patellofemoral lesions are not necessarily associated with anterior knee pain, **we suggest that they could** be left alone. This recommendation is only applicable to patellofemoral lesions which are found incidentally whilst addressing other pathology.

1. Introduction

The role of patellofemoral cartilage lesions in the aetiology of anterior knee pain (AKP) is unclear [1]. Such defects are recognised incidentally [2-5] in up to 30% of patients [6] having arthroscopic treatment for other pathologies. Anterior knee pain can occur without chondral lesions [7-9], alternatively chondral lesions may be asymptomatic [7, 10, 11]. Advocates of conservative management suggest that surgical treatment is indicated in less than 10% of patients with chondromalacia patella [12], whereas other authors have described a role for arthroscopic interventions [4, 13, 14] but only in specific groups where AKP was the principle problem. Therefore, it remains unclear exactly how to manage patellofemoral lesions when they are found incidentally. Hypothetically, if such lesions were to be strongly associated with AKP then this may provide a rationale for intervention.

There is some evidence of a relationship between AKP and patellofemoral pathology. In a case control study using magnetic resonance imaging (MRI), a higher proportion of chondral lesions was found in athletes with AKP than in pain free matched controls [15]. However, this study established AKP with a non validated questionnaire and MRI has, at best, 83% sensitivity in detecting high grade cartilage lesions [16]. Arthroscopy is considered to be the gold standard for diagnosis because it allows good views of the patellofemoral joint [17]. Arthroscopic findings were compared with MRI in a study of 56 young military cadets with AKP [16], where symptoms were stratified as AKP alone, clinical AKP syndrome with negative provocation tests and clinical AKP syndrome with positive provocation tests. There was no correlation between this stratification of symptoms to the grade of chondromalacia patellae and the study group of active young soldiers may not be generalizable to the patients encountered in civilian practice.

The aim of this study was to establish the strength of association between incidental patellofemoral lesions and AKP. We used a sample undergoing arthroscopy for typical indications such as meniscectomy and ligament reconstruction, anticipating that a proportion of these patients would have incidental patellofemoral lesions. The principle hypothesis was that incidental patellofemoral lesions would be associated with anterior knee pain, at least to some degree. An

additional objective was to confirm the sites and frequencies of patellofemoral lesions identified in a typical arthroscopic population.

2. Patients and Methods

This was an observational cross section study with data collected prospectively. A power calculation was performed where the effect size model for correlation studies [18] was used. To identify a large effect (strong association between variables) with statistical power of 0.8, at the 0.05 probability level, a minimum sample of 30 patients would be required. Local board ethical approval was obtained and all patients provided fully informed written consent prior to participation. Diagnosis was established by standard clinical assessment and appropriate radiological investigation. This included plain radiographs for all patients (Orthogonal standing views with Merchant's patella view) with MRI reserved for those cases where the diagnosis was uncertain. The sample was designed to identify patellofemoral lesions found incidentally by including typical patients undergoing knee arthroscopy but also excluding those patients with known patellofemoral lesions. Thus all patients listed for arthroscopy at the authors' institution during the study dates (January to October 2009) were considered for inclusion as a consecutive series. The inclusion criteria were those conditions in which it would be reasonable to use knee arthroscopy for diagnostic or therapeutic purposes with pre-operative diagnoses broadly grouped as meniscal injuries, ligament ruptures and cartilage disruption in the medial or lateral compartments (Table 1). Exclusion criteria were those patients with a history of any previous arthroscopic surgery, patellofemoral realignment surgery, patellofemoral instability, patella tendonitis, patella fracture, patellectomy, chondromalacia patella or known patellofemoral arthritis, Ehlers-Danlos syndrome, inflammatory arthritis or chronic pain conditions. Two male patients, thought to have meniscal injuries, were found at surgery to have pigmented villonodular synovitis and were excluded from the study, due to confounding generalised pain. Data were prospectively collected from 64 patients (48 male, 16 female), with a mean age of 42 (range 16 to 72). A pre-operative

pain assessment was performed by a single research physiotherapist and compared to the findings of arthroscopies performed by a single consultant surgeon, who was blinded to the pre-operative assessment.

The research physiotherapist (SJ) assessed each patient to establish the nature and location of knee pain, in the two hours prior to surgery. The presence or absence of knee pain, together with its location, was then mapped by three distinct methods:

1. The photographic knee pain map (PKPM) is a validated instrument designed to determine knee pain location [19]. Patients annotated pain location using crosses upon a photographic representation of a pair of knees. A template divides the knee into nine anterior zones, and a transparency of this template was subsequently used to score the annotated PKPM. Anterior knee pain was considered present when pain was located in at least one of the four extensor mechanism zones (medial patella, lateral patella, quadriceps tendon or patellar tendon) (Fig 1).
2. Patients were asked to indicate pain location on their own knee by pointing with one finger. This was observed by the research physiotherapist who categorised the locations indicated into zones according to the PKPM template. Patients were permitted to indicate pain in as many locations as necessary. It has been suggested that patients can localise pain accurately in this way [20, 21].
3. The research physiotherapist systematically palpated on the anterior surface of each knee to identify the location of any tenderness. Again this was classified into zones according to the PKPM template. The location of tenderness has been shown to be consistent with the site where patients perceive their pain [22].

Arthroscopic procedures were performed by one surgeon (DFK) using standard anterolateral and anteromedial portals. Each area of the patellofemoral joint was systematically examined in a logical sequence. Under direct vision the cartilage was probed to identify areas of softening, fibrillation, fissuring or fragmentation. In most cases a 30° arthroscope allowed adequate visualisation whilst probing the patellofemoral joint. When views were suboptimal due to a shallow

line of vision looking upon areas of fragmented cartilage then a 70° arthroscope was introduced because higher angle lenses increase the accuracy of the arthroscopic evaluation [23]. The location and severity of any patellofemoral lesions were recorded according to the International Cartilage Repair Society (ICRS) grading system [24] where lesion depth is graded as 0=normal, 1=nearly normal, 2=abnormal, 3=severely abnormal, and 4=penetrating subchondral bone. During analysis, a threshold of ICRS grade ≥ 2 generated nominal data where “high grade” chondral lesions were at least abnormal. The term “low grade” thus refers to normal or nearly normal cartilaginous appearances.

Statistical analysis was performed using SPSS version 20 (SPSS Inc, Chicago, Illinois) with the level of significance set at $p < 0.05$. Pearson’s chi-squared contingency coefficient (χ^2) was used to compare association between pre-operative variables (pain location) and the nominal data for patellofemoral chondral lesions, generating a value which indicates the strength of association ranging between 0 (no association) and 1 (maximum association). When interpreting agreement other authors [25] have grouped values with the following descriptive terms: “very good” for 0.81-1.0, “good” for 0.61-0.8, “moderate” for 0.41 - 0.6, “fair” for 0.21 - 0.4 and “poor” for 0.01 - 0.2.

3. Results

The principle diagnosis was confirmed by arthroscopy (Table 1). Anterior knee pain was annotated on 34 of the PKPM (53%), was pointed to by 35 of the patients (55%), and was palpated in 30 patients (47%). Patellofemoral lesions were found in 42 patients, of which 30 were high grade lesions. These were most frequently located in central areas, particularly the mid central patella and the central trochlea (Fig 2). In some instances, fair associations were found between pain location and patellofemoral lesions (Table 2). Statistically significant, fair associations were found with tenderness palpated on the quadriceps tendon ($P=0.029$, $\chi^2=0.26$), the medial patella ($P=0.007$, $\chi^2=0.32$) and the patella as a whole (medial or lateral patella zones, $P=0.047$, $\chi^2=0.24$). **In addition,**

we observed a fair association between PKPM annotation of the whole patella, which was trending towards, but did not reach statistical significance ($P=0.052$, $\chi^2=0.24$).

4. Discussion

Our study identifies patellofemoral lesions with greater frequency in the central areas of both the patella and trochlea with comparable frequencies of lesions on both lateral and medial sides (Fig 2). In contrast previous authors [26, 27] have observed a higher frequency of lesions on the medial facet of the patella.

We found a fair association with the subjective pain localisation (annotated PKPM) for the whole patella, which was trending towards significance. The fair associations with objective tenderness palpated on the medial patella, quadriceps tendon and the whole patella did reach statistical significance but their magnitude was at best, fair - lacking the strength to be confident of consistent correlation. Subsequently these results could be interpreted as associations without clinical significance. Certainly there was insufficient strength of association to explore further for more subtle associations using individual areas of the ICRS or PKPM templates. On this basis we hypothesise that intervention may not necessary for incidental patellofemoral lesions but we recognize that further interventional studies are required to prove this theory.

Other studies which considered the same factors (AKP and cartilage lesions) did not find any significant association [15, 16, 28]. The multi-factorial aetiology of patellofemoral pain [20, 29, 30-32] may explain this lack of strong association. Chondral lesions may act together with other pathomechanical factors such as patella alta, trochlea dysplasia, lateral tibial tubercles and soft tissue imbalance to produce pain [30]. Pain may derive from alternative anatomical structures and subchondral bone, synovium, retinaculum, muscle, nerve and skin have been identified as potential sources of pain [20]. Articular cartilage is aneural and thus reported pain is thought to be secondary to synovial irritation or subchondral bone overloading [30]. Several processes may contribute to a loss of homeostasis [33] within the knee, where pain may result from exceeding the knee's

functional envelope [34]. Patellofemoral pain is often diffuse in nature [26, 32, 35] and the lack of strong association found here could reflect the difficulty patients may have in localising their pain, despite our methods to accurately detect AKP.

Those authors who initially described a role for arthroscopic intervention in chondromalacia patella found it to be beneficial [4, 13, 14], but this effect was not observed in a randomised controlled trial comparing arthroscopic shaving to exercise regimes [31]. In a cohort of ACL reconstruction patients, asymptomatic cartilage lesions found incidentally at different sites in the knee were left untreated, but this did not diminish clinical outcomes [5]. Other studies which considered the same variables found no association [15, 16, 28].

In previous studies AKP has been identified with questionnaires [10], provocation tests [15], or clinical diagnostic criteria for chondromalacia patellae [16, 36, 26]. Questionnaires may not specify pain location [37], provocation tests have poor diagnostic accuracy [29, 38] and chondromalacia patellae has been clinically described with “pain that is not well localised” [26]. The methods of this paper were thus expanded to specifically identify pain located in the anterior knee. We used the PKPM [19] which has been shown to be a valid and reliable method for identifying knee pain location. Once categorised into anatomical zones, knee pain location can then be considered separately or grouped as regional pain syndromes. We considered pain located in the four extensor mechanism zones to be representative of AKP (Fig 2). Pain was also elicited by patient indication and by palpated tenderness, with findings categorised according to the PKPM template for consistency. The modality for locating pain which would provide the fairest representation was uncertain, which is why three different methods were employed. Importantly, palpation of the knee was performed last during assessment, to avoid influencing the patients’ subjective localisation of pain.

This study has potential limitations. A consecutive series of typical arthroscopies was chosen in order to identify patellofemoral lesions which were incidental. However the compromise for this approach is inclusion of a range of pathologies (table 1) and we acknowledge that this is a

potential cause of confounding in pain reporting. To compensate, patients were allowed to identify pain in as many different locations as necessary and the various zones of the PKPM template facilitated the filtering of specific regional pains, such as AKP. Pain is often reported in two or three distinct regions [21] so providing only one opportunity to locate pain would not accurately reflect patients' subjective symptoms.

This study is supported by several features of its design. At both stages of assessment the use of single observers reduced the effect of interpretation bias. Prospective data was collected using arthroscopy, considered to be the diagnostic gold standard [17] and reported according to the recognised ICRS standard [24]. The surgeon was blinded to pre-operative recordings to eliminate reporting bias. Chronic knee pain is punctuated by episodes of more intense pain [39] and we hypothesised that the nature and location of pain would change with long time frames. Accordingly pain assessments were performed within two hours of surgery to minimise this effect.

5. Conclusion

Due to its multifactorial aetiology, AKP cannot necessarily be attributed to patellofemoral lesions alone. We chose a typical arthroscopic sample and excluded known patellofemoral pathology in order to identify incidental patellofemoral lesions. In a few instances associations with AKP were found. However, the magnitude of these associations were at best fair and hence **could be** interpreted as clinically insignificant. We hypothesise that intervention for incidental patellofemoral lesions **may be** unnecessary but a further randomised controlled trial is needed to establish if any such intervention can be justified.

Table 1. Pre-operative diagnosis compared to operative findings

Category	Details	Pre-op diagnosis	Operative diagnosis
Meniscal injury	Medial	31	27
	Lateral	3	3
	Both	2	6
Ligament rupture	ACL without meniscal injury	9	8
	ACL with meniscal injury	7	8
	PCL	1	1
	MCL	1	1
Cartilage disruption	Medial	10	8
	Lateral	1	1
Miscellaneous	ITB syndrome	1	1
	PVNS*	-	2

ACL = anterior cruciate ligament; PCL = posterior cruciate ligament; MCL = medial collateral ligament; MPFL = medial patellofemoral ligament; ITB = Iliotibial band; PVNS = pigmented villonodular synovitis.

*These 2 patients were excluded due to the confounding effect of generalised pain. 66 patients thus underwent arthroscopic surgery but 64 remained in the sample for analysis.

Table 2. Associations between pain location and patellofemoral lesions, presented for each method of detecting anterior knee pain

Pain location	PKPM annotation		Patient pointing		Palpated tenderness	
	χ^2	p Value	χ^2	p Value	χ^2	p Value
Medial patella	0.11	0.39	0.04	0.74	0.32	0.007
Lateral patella	0.14	0.25	0.07	0.57	0.07	0.57
Patella*	0.24	0.052	0.08	0.53	0.24	0.047
Patella tendon	0.07	0.56	0.43	0.73	0.00	0.99
Quads tendon	0.08	0.54	0.17	0.17	0.26	0.029
Anterior knee**	0.19	0.12	0.04	0.77	0.18	0.14

PKPM = photographic knee pain map [19]. Associations were calculated using Pearson's chi squared correlation coefficient (χ^2) with the reported significance levels (p).

*Pain located in the medial OR lateral patella zones.

**Pain located in any of the four extensor mechanism zones.

Fig 1.

The photographic knee pain map (PKPM) is a validated instrument to determine knee pain location [19]. Patients annotate pain location on this photographic representation of a pair of knees using crosses. In this diagram the overlaid template divides the PKPM into nine anterior zones for each knee. The extensor mechanism zones are marked; QT: quadriceps tendon, MP: medial patella, LP: lateral patella, PT: patella tendon. The shaded area on the left knee indicates where an annotation would have been scored as anterior knee pain.

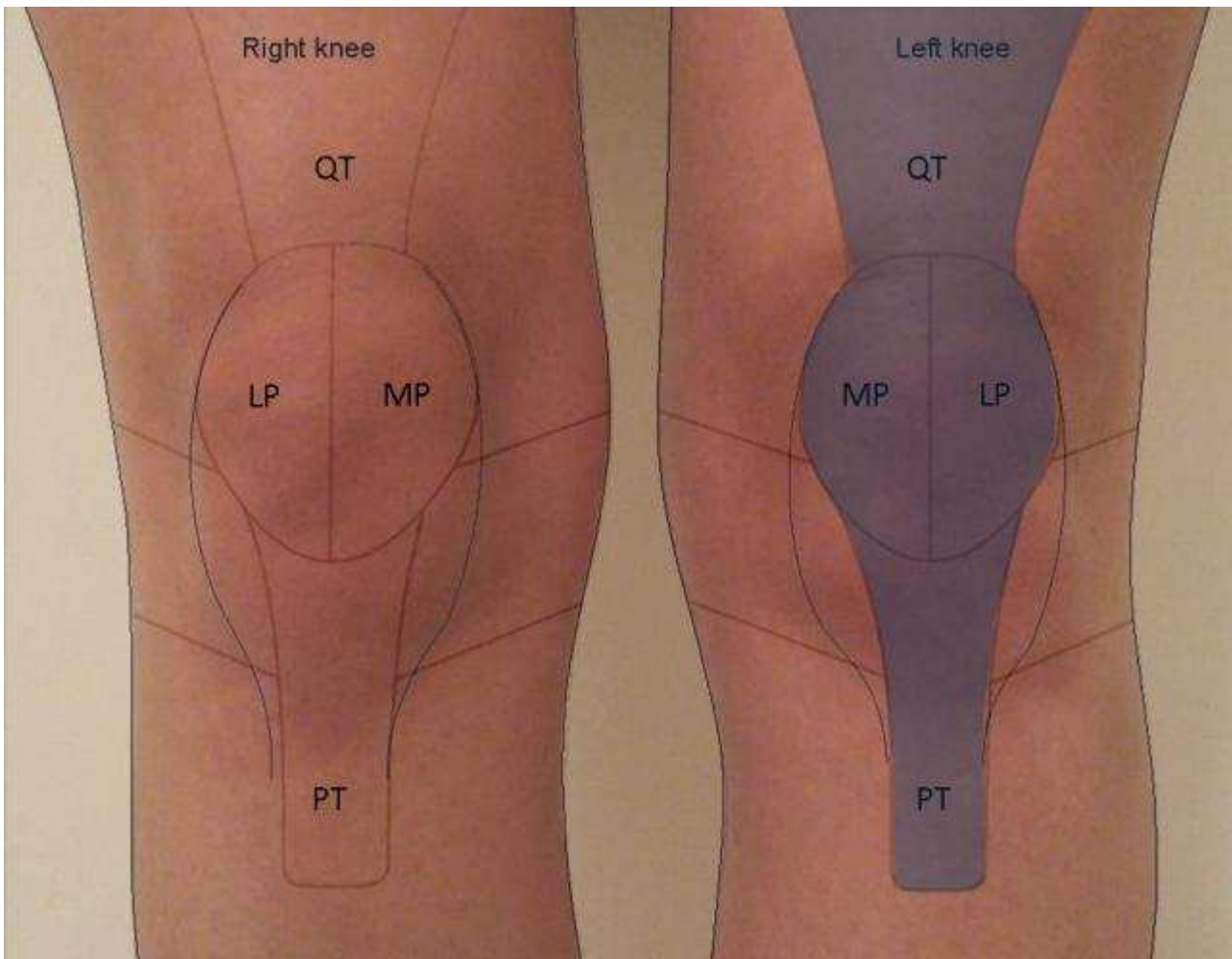
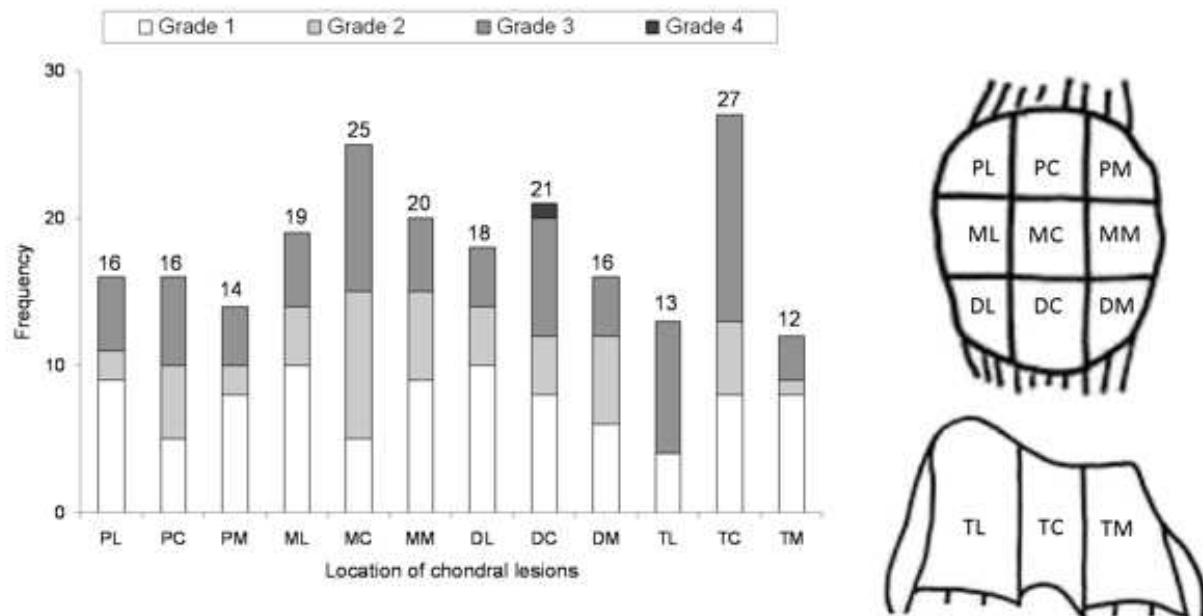


Fig 2.

Frequency of chondral lesions located according to the ICRS [24] matrix of the patellofemoral joint.

Frequencies displayed for each ICRS [24] zone are stratified by lesion grade. Frequency



summations are as follows: Medial = 62, Central = 89, Lateral = 66.

PL = proximal lateral patella; PC = proximal central patella; PM = proximal medial patella; ML = middle lateral patella; MC = middle central patella; MM = middle medial patella; DL = distal lateral patella; DC = distal central patella; DM = distal medial patella; TL = trochlea lateral; TC = trochlea central; TM = trochlea medial.